

Unusual thyroid dysfunction in a patient treated with Alemtuzumab for Relapsing-remitting Multiple sclerosis

Satish Artham*, Mona Abouzaid*, Ashwin Joshi^

*Specialist Registrar, ^Consultant, Sunderland Royal hospital



City Hospitals Sunderland
NHS Foundation Trust

Introduction

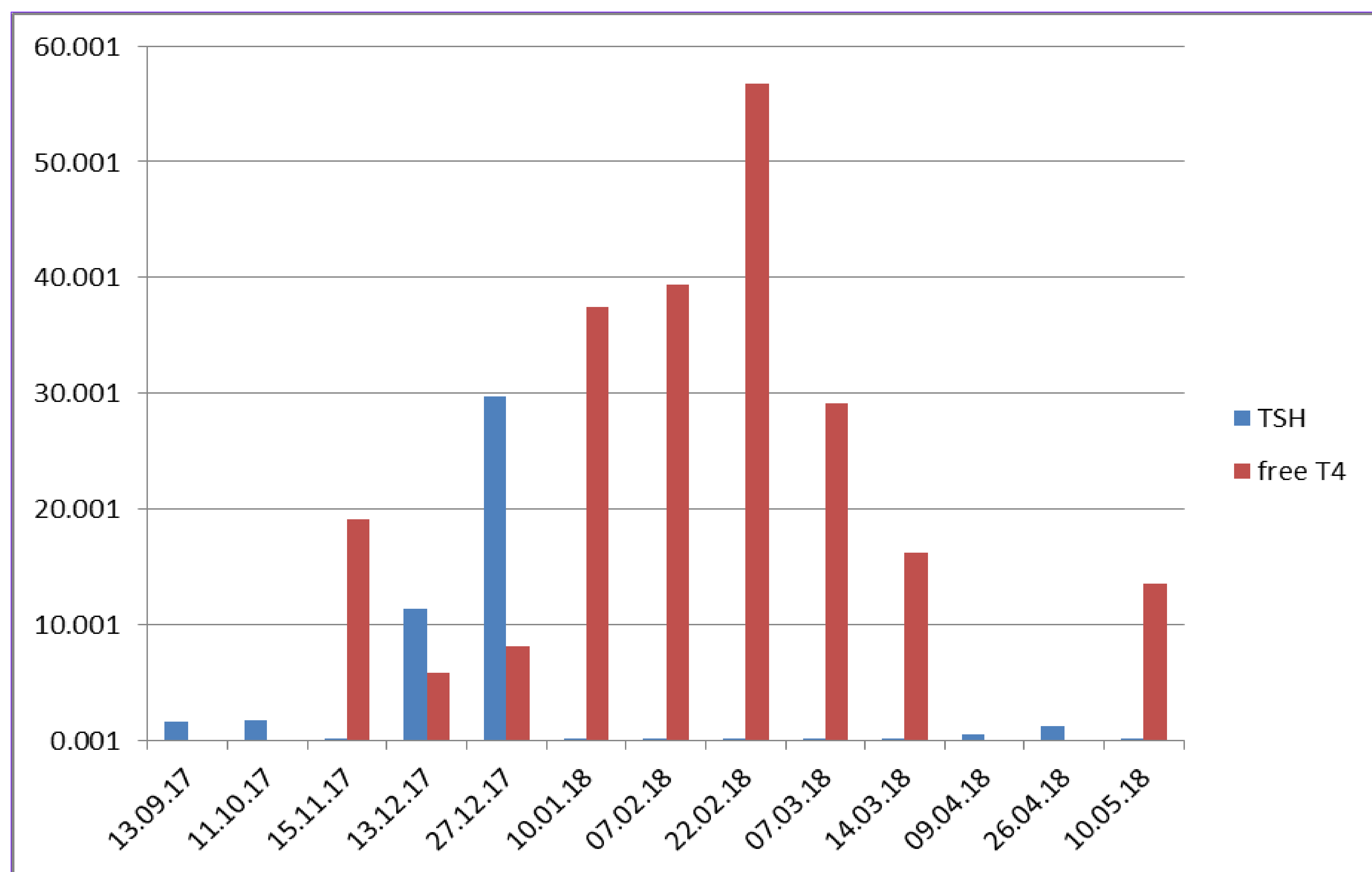
Alemtuzumab is humanized monoclonal antibody (anti-CD52) used in the treatment of relapsing–remitting multiple sclerosis (MS). The 5-year incidence of thyroid adverse events in phase 3 clinical trials is up to 40.7%(1). In most cases, the thyroid dysfunction is mild and easily manageable and only few serious thyroid adverse events have been reported. Hyperthyroidism, particularly Graves Thyrotoxicosis is more common than hypothyroidism. National Institute for Health and Care Excellence (NICE) has published technology appraisal guidance on the use of Alemtuzumab for the treatment of active relapsing-remitting Multiple Sclerosis in May 2014. We describe a case of unusual thyroid dysfunction in a patient with relapsing remitting MS treated with Alemtuzumab.

Case

A 30 years old female was diagnosed with relapsing-remitting MS at the age of 15yr. She was treated with Natalizumab between July 2009 and November 2014. She conceived and stopped Natalizumab in November 2014. Unfortunately she had an early miscarriage. She had an MS relapse in February 2015 whilst off the treatment. She conceived again in March 2015 and was off treatment until January 2016. Her TSH was normal between February 2008 and September 2017. She was commenced on Alemtuzumab in April 2016 and had a second treatment dose in April 2017. She had routine thyroid function tests (TFT) as part of follow- up after treatment with Alemtuzumab. Initial blood tests showed suppressed TSH at <0.02mIU/L, normal free T4 at 19.1pmol/L and free T3 at 6.6pmol/L suggesting subclinical hyperthyroidism. She had family history of thyroid dysfunction with her sister treated for Graves' thyrotoxicosis in the past. As she was asymptomatic, monitoring was continued. Repeat TFT's in a months' time showed TSH 11.32mIU/L and free T4 5.8pmol/L suggesting overt hypothyroidism. Thyroid peroxidase (TPO) antibodies were 61.7 (0-34) and TSH receptor antibodies (TRAb) >40. She was subsequently commenced on Levothyroxine 75mcg once a day. Repeat TFT's after 3weeks revealed TSH 0.09 mIU/L and free T4 37.5pmol/L. Levothyroxine dose was reduced to 25mcg once a day. Further interval testing showed TSH <0.02 mIU/L and free T4 =39.4pmol/L; hence Levothyroxine was completely stopped. She had Thyroid isotope uptake scan which showed increased (6.5%) uniform uptake at 20min suggestive of hyperthyroidism secondary to Graves' disease. Subsequent TFT's 2weeks later showed overt thyrotoxicosis with TSH<0.02 mIU/L, free T4 56.8pmol/L and free T3 29.3pmol/L. At this stage, she was symptomatic with palpitations, anxiousness, itching of skin and bowel disturbance. She was then commenced on anti-thyroid medication Propylthiouracil (PTU) 150mg twice a day and Propranolol 10mg three times a day. She improved both clinically and biochemically with TSH 0.11mIU/L, free T4 13.5pmol/L and free T3 7pmol/L in May 2018.

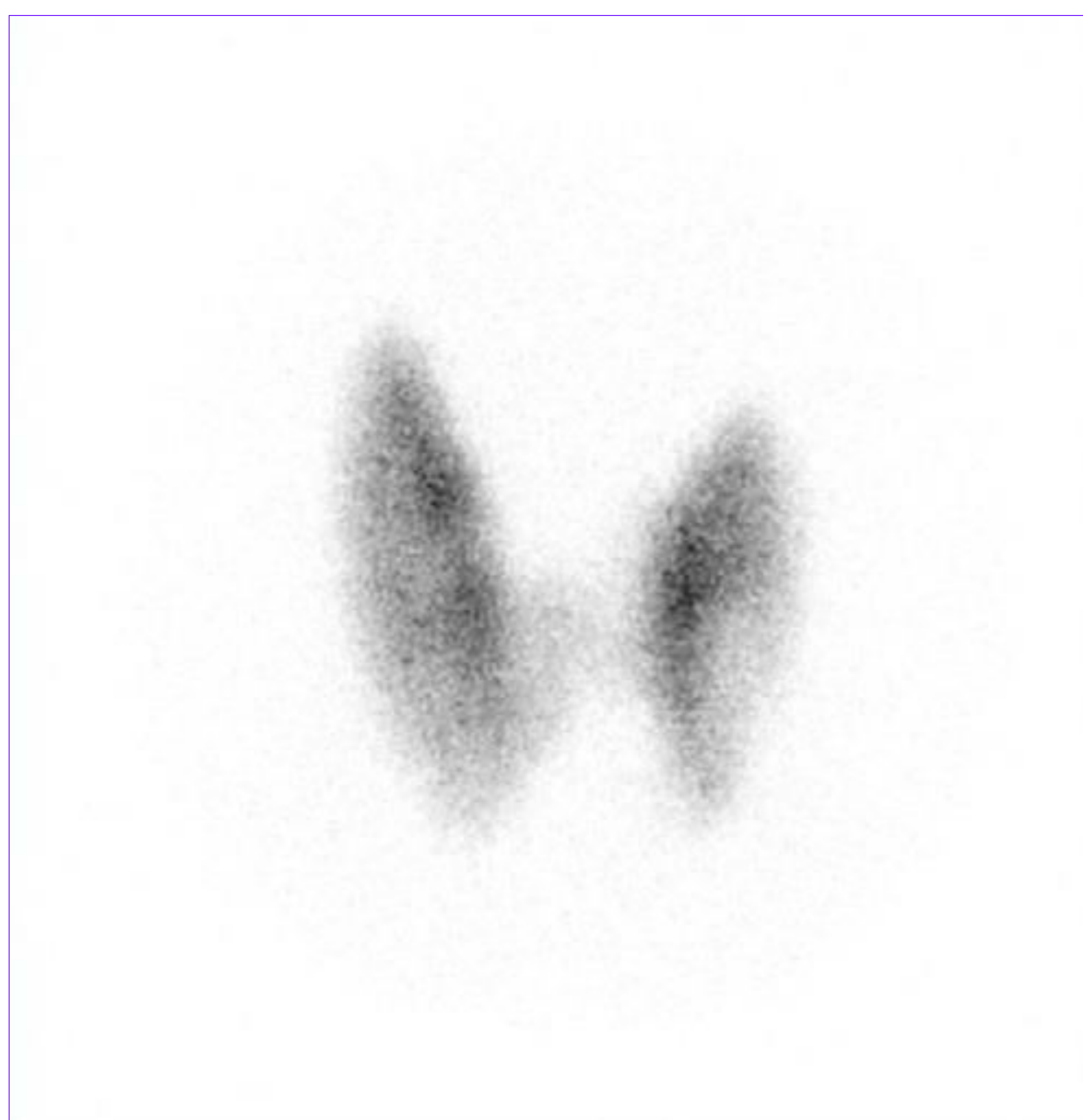

Fig 1 . Radio-isotope uptake scan



Graph 1 . TSH and free T4 levels

Discussion

Alemtuzumab treatment provides significant benefits for patients with relapsing remitting MS. Treatment with alemtuzumab is associated with increased risk of autoimmune conditions including thyroid problems, immune thrombocytopenic purpura, inflammatory bowel disease, autoimmune nephropathy, etc. Thyroid autoimmunity is the commonest with most studies reporting between 17%-34%(2). Graves' disease occurs in 60-70% of the cases. Onset of thyroid disease was variable ranging from 2months to 107months but most developed within 3years of initiation of treatment(3). Hyperthyroid patient can change into hypothyroid or euthyroid. It is recommended to do regular monitoring of thyroid function to diagnose any thyroid dysfunction and treat appropriately. Monitoring may be required for many years as patients can develop thyroid problems even years after the treatment.

Conclusion

Thyroid dysfunction is the commonest autoimmune disease in patients treated with Alemtuzumab for relapsing-remitting MS. Graves' thyrotoxicosis being the most common subtype. Our patient initially had a hypothyroid phase with positive TRAb and TPO antibodies, subsequently converting into hyperthyroidism, which is uncommon.

References

- Decallonne B, Bartholomé E, Delvaux V, et al. Thyroid disorders in alemtuzumab-treated multiple sclerosis patients: a Belgiaconsensus on diagnosis and management. *Acta Neurol Belg* 2018;118:153–159.
- Tuohy O, Costelloe L, Hill-Cawthorne G, et al. Alemtuzumab treatment of multiple sclerosis: long term safety and efficacy. *J Neurol Neurosurg Psychiatry* 2015;86(2):208–215.
- Pariani N, Willis M, Muller I, Healy S, Nasser T, McGowan A, Lyons G, Jones J, Chatterjee K, Dayan C, Robertson N, Coles A, Moran C. Alemtuzumab-Induced Thyroid Dysfunction Exhibits Distinctive Clinical and Immunological Features, *The Journal of Clinical Endocrinology & Metabolism* 2018;103;8:3010–3018.

