

Rapid onset hirsutism in a post-menopausal woman with an ovarian cyst

Dr. Meenakshi Parsad, Dr Faizan A. Rao, Tishena Lloyd , Dr Livoon Chong

Royal Hampshire County Hospital, Winchester, UK

email: meenakshi19@doctors.org.uk , faizanali.rao@doctors.org.uk



Introduction

Sertoli-Leydig cell tumours are rare comprising less than 0.5 % of all primary ovarian cancers. 1

These mainly affect younger patients aged 30 years or below.1,2

Heterologous Sertoli-Leydig cell tumours with dominant cystic component are even rarer.1,2,3,4

Virilisation is seen in 30-40 % of cases. 1

We present a case of severe hirsutism and virilisation in a post-menopausal woman with the final diagnosis of a heterologous Sertoli-Leydig cell tumour with a dominant cystic component.

Case Report

- A 66-year-old lady was referred to the Endocrine Department with a one year history of rapidly developing severe hirsutism involving the face, chest , abdomen and limbs as well as thinning of scalp hair.
- She was clinically hirsute.
- Her blood pressure was 156/89 mmHg and she had a BMI of 34
- Testosterone was raised at 11.9 nmol/L, serum cortisol was 461 nmol/L and TSH was 9.29 mu/L with a FT4 of 14.

Further Investigations and Management

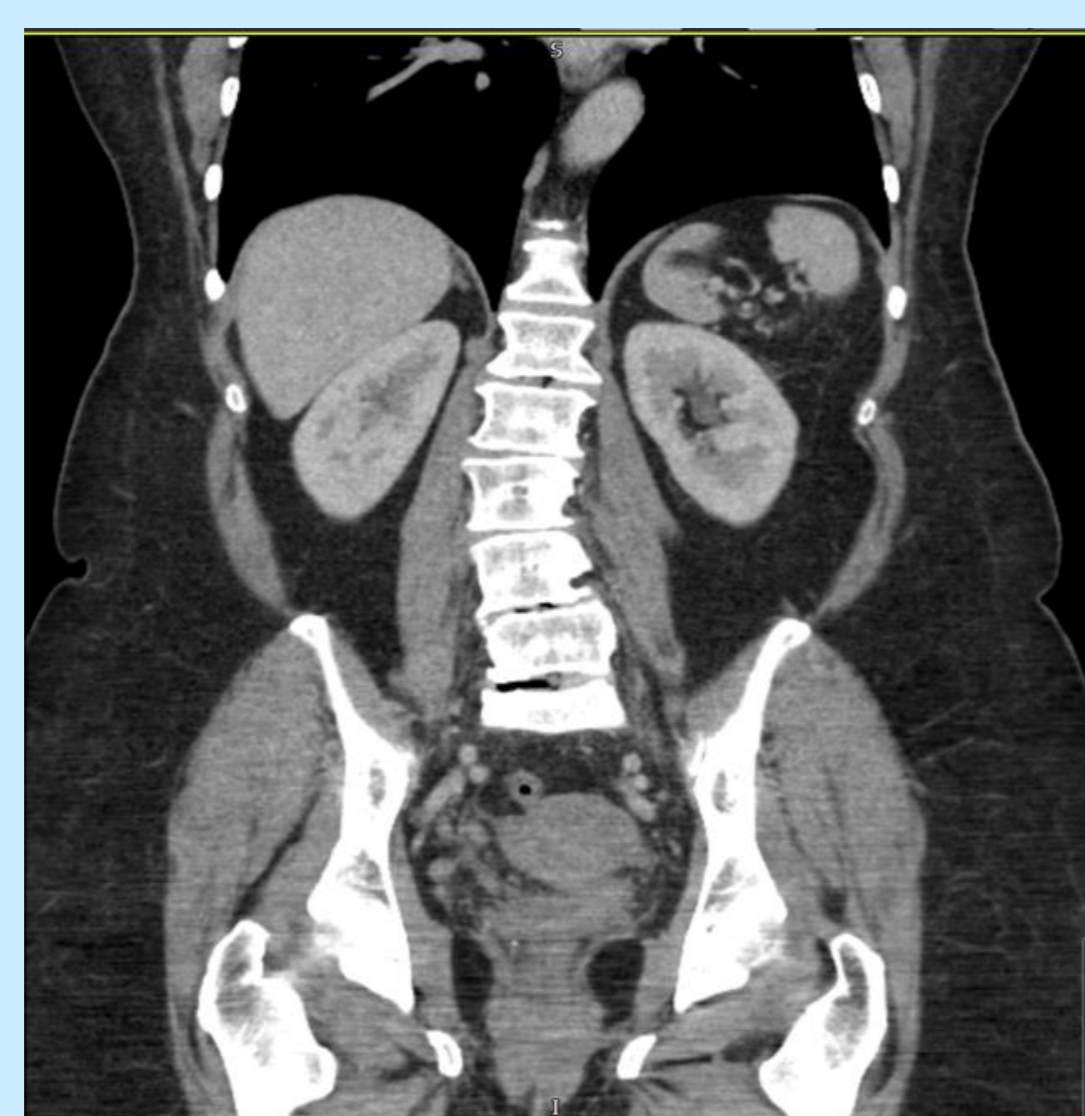
24 hour urine cortisol was normal at 80 nmol (0-146) and 1 mg overnight dexamethasone suppression test showed adequate suppression with morning serum cortisol of 24 nmol/L.

CT scan of the abdomen showed normal adrenal glands but a large left ovarian cyst measuring 10 x 11 x 8 cm in size.

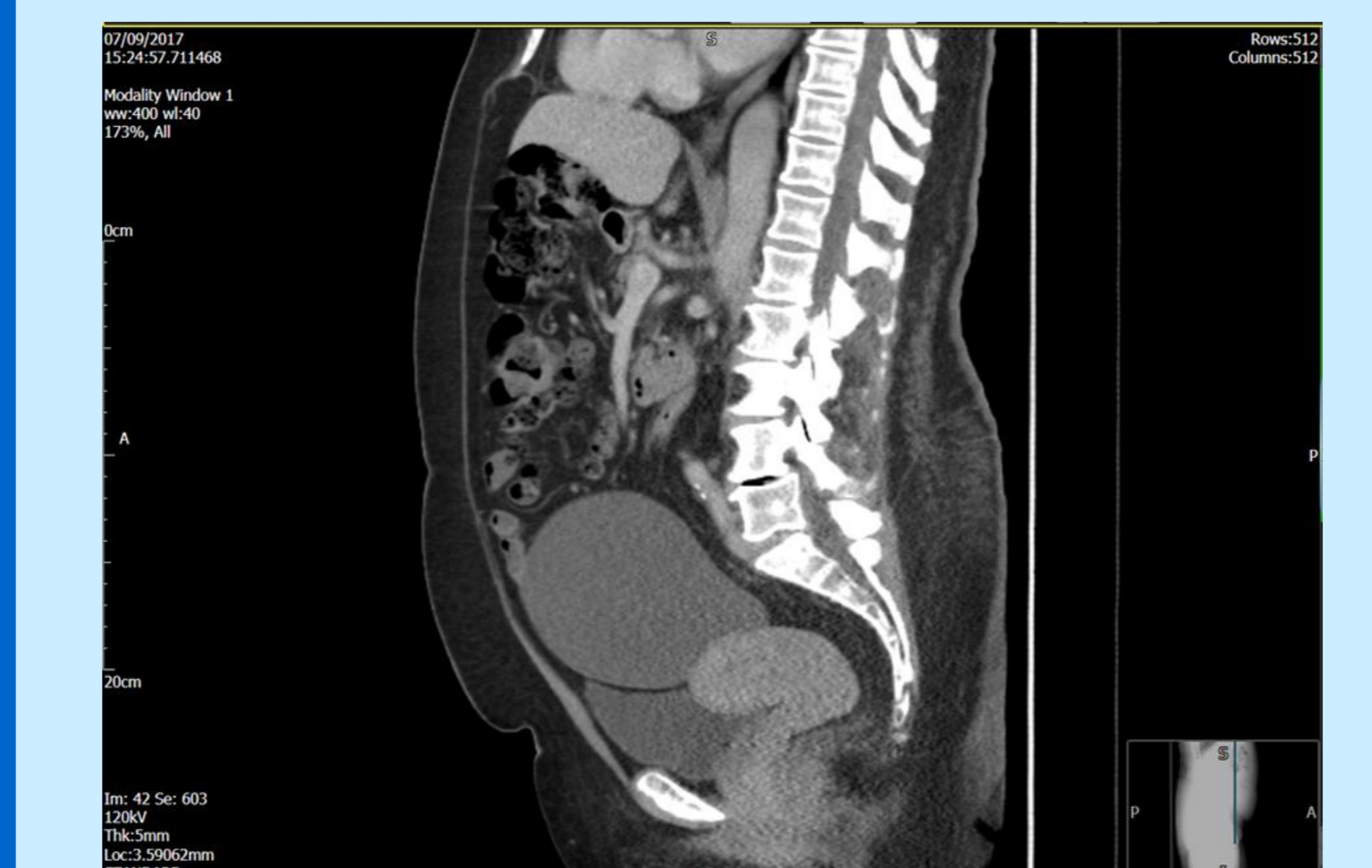Transvaginal ultrasound showed a large uni-locular ovarian cyst measuring 12.7 x 8.3 x 9 cm with some thick septations seen. CA 125 was normal at 7 Ku/L (N 0-35).

Initially there were uncertainties regarding direct causal effect of the diagnostic findings with the clinical picture . However, after MDT discussions the patient eventually had surgical removal of the ovarian cyst.

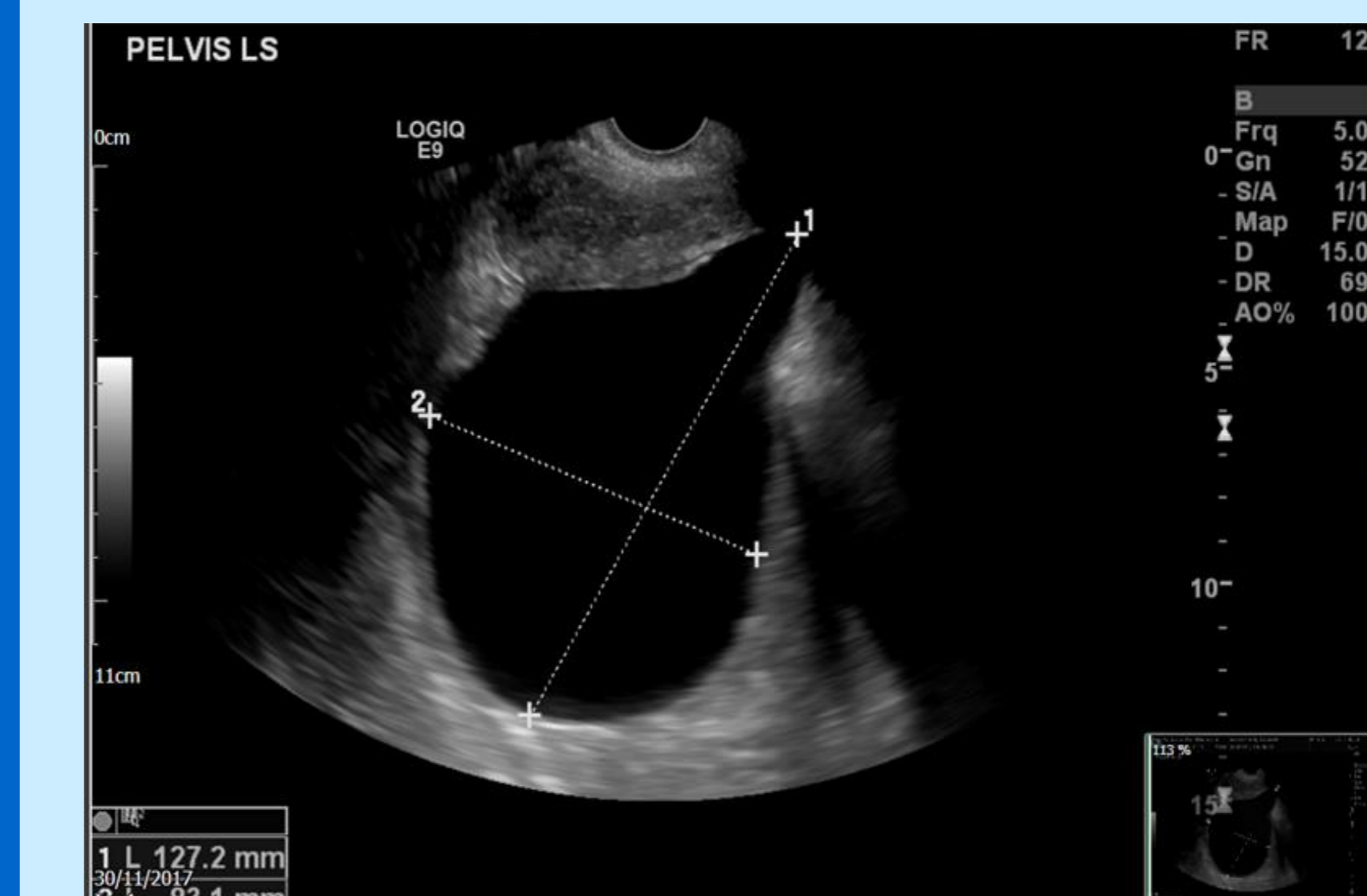
CT Abdomen – Normal Adrenals



CT Abdomen – Ovarian Cyst



Ultrasound Scan – Ovarian Cyst



Outcome and Discussion

Testosterone level normalised to 0.5 nmol/L once the ovarian cyst was removed surgically ; the patient also had significant improvement in hirsutism as well.

Initial histological analysis of the wall of the ovarian cyst was ambiguous and even after review by the Histopathology department at our tertiary centre, the two main differential diagnoses were mucinous cystadenoma with stromal luteinisation and hilar cell hyperplasia or heterologous Sertoli-Leydig cell tumour with dominant mucinous cystic component. The latter was finally the favoured diagnosis when correlated clinically.

Conclusion

- This case illustrates the importance of lateral thinking especially when dealing with uncommon presentations of rare diseases.
- Multidisciplinary approach is vital in correct diagnosis and management in such situations
- Revisiting imaging modality and subsequently re-analyzing histopathology in a tertiary center were essential in our case and would be our recommendation to our endocrinology colleagues if faced with similar cases.

References

1. Young RH, Scully RE. Ovarian Sertoli-Leydig cell tumours. A clinicopathological analysis of 207 cases. Am J Surg Pathol. 1985;9:543–569
2. Tandon R. *et al*/A Rare Ovarian Tumor – Sertoli-Leydig Cell Tumor With Heterologous Element. Medscape General Medicine. 2007;9(4):44.
3. Virk R. *et al*/Mucinous adenocarcinoma as heterologous element in intermediately differentiated Sertoli-Leydig cell tumor of the ovary. Pathology Research and Practice, 2010, 206 (7) , pp. 489-492
4. Li Liang *et al*, Ovarian Sertoli-Leydig Cell Tumor with Predominant Heterologous Mucinous Differentiation and Foci of Hepatocytic Differentiation: Case Report and Review of The Literature, Ann Clin Lab Sci May-June 2015 45:348-351