

Atypical Presentation of Familial Hypocalciuric Hypercalcaemia (FHH):

Would you recognise it?

Kaenat Mulla¹, M. Asim T. Khan^{1,2}, Suhier Elshowaya^{1,2}, Gideon Mlawa^{1,2}

1. King George Hospital –London 2. Queen's Hospital –London

INTRODUCTION

Hypercalcaemia is a commonly encountered biochemical abnormality. The most common causes of hypercalcaemia are primary hyperparathyroidism and malignancy.

CASE:

We present a 53-year-old female, who was referred to the endocrinology clinic for further investigation of a persistent hypercalcaemia associated with low-to-normal parathyroid hormone level (PTH) (1.5pmol/L). She suffered from chronic anergia, generalised myalgia and recurrent renal stones.

Figure 1.

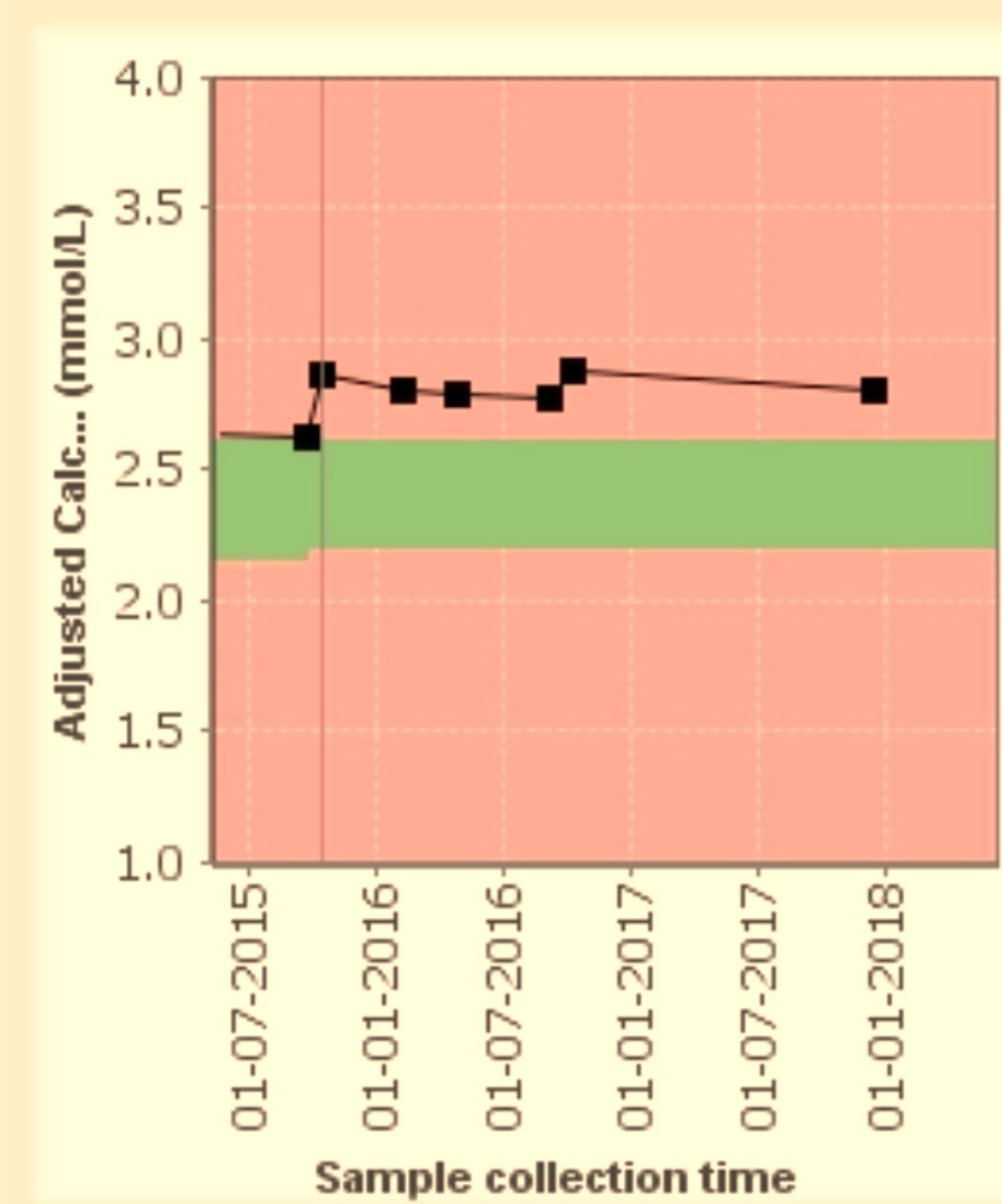


Figure 2.

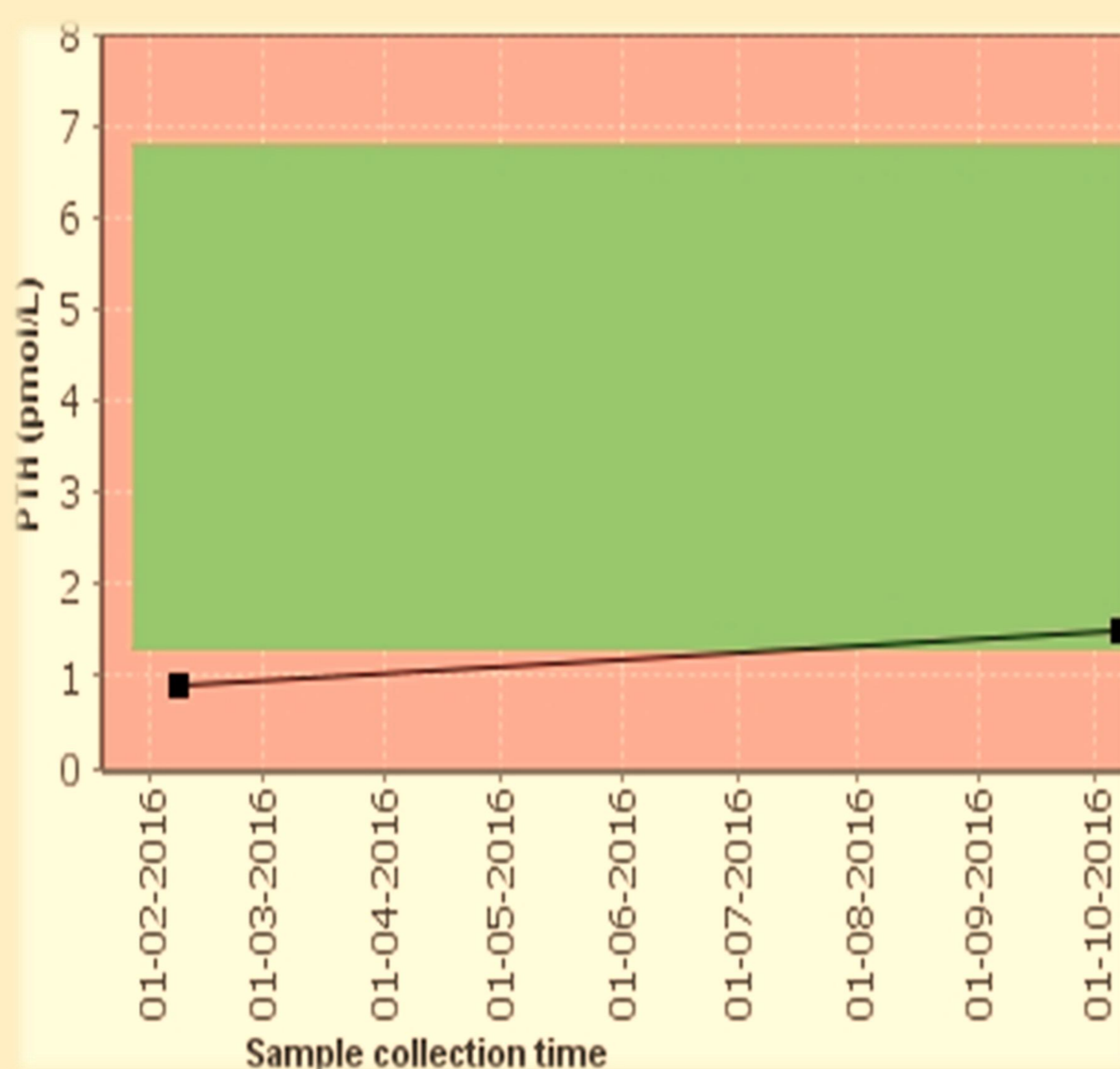


Figure 1- graph showing the trend in her serum adjusted calcium level

Figure 2- graph showing her PTH level

There was a significant family history; her father, brother, sister and grandson were also known to have hypercalcaemia. Prior to her endocrinology referral, she was managed by the urology team for recurrent renal stones for several years. She did not take any regular medications. Her past medical history consisted of fibroadenoma of the right breast, cervical polyp and recurrent urinary tract infections likely due to renal stones.

She was extensively investigated for secondary causes of hypercalcaemia, including malignancy. The patient had a myeloma screen; a CT scan of her thorax, abdomen and pelvis; and serum ACE levels (14.2nmol/L). There were no positive findings.

Ultrasound scans of her parathyroid and thyroid glands were suggestive of an atypical and equivocal right inferior parathyroid adenoma. A sestamibi scan was conducted, which showed appearances were most likely due to adenomatous hyperplasia of the parathyroid rather than a solitary adenoma.

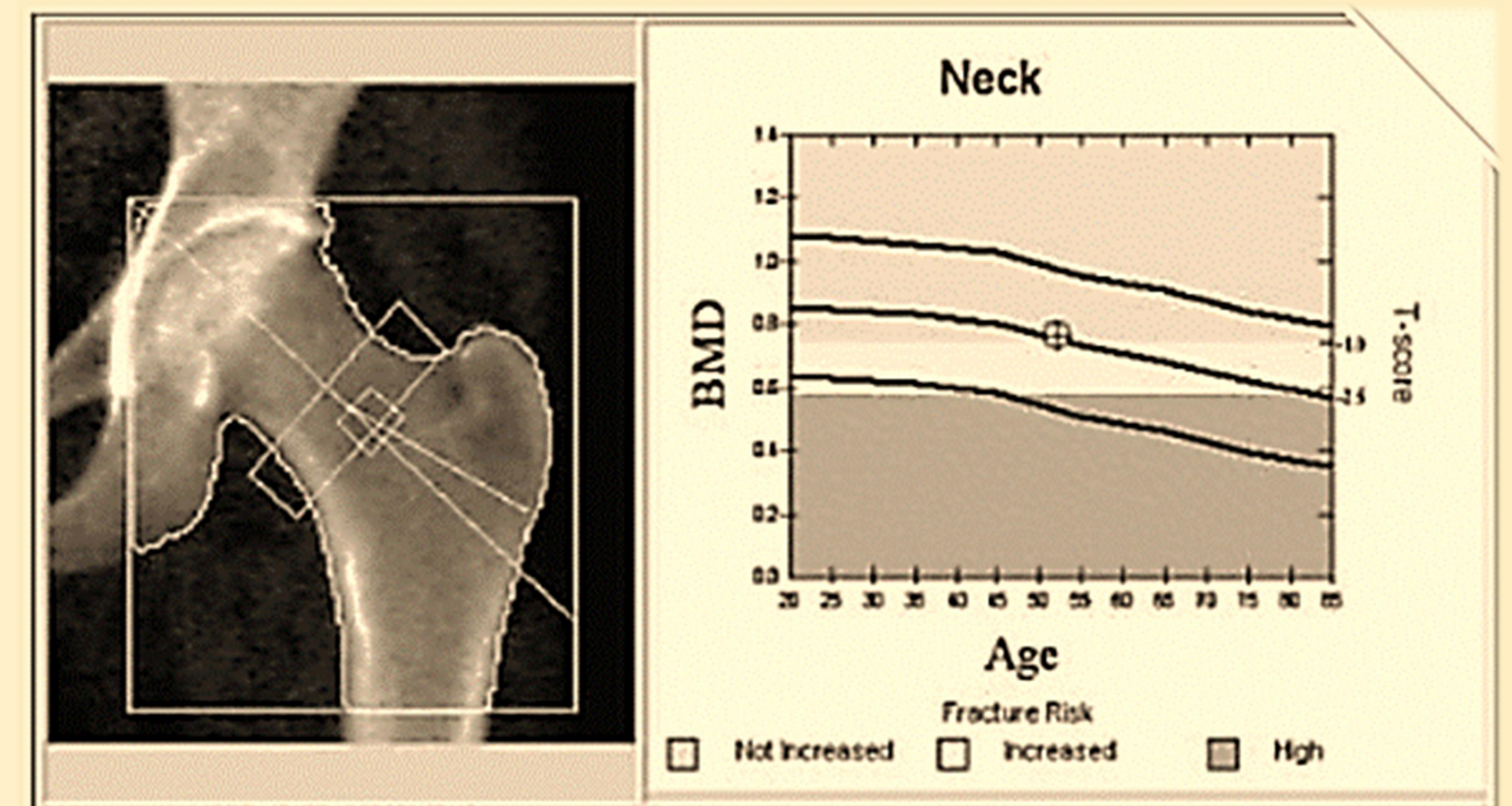
Finally, the genetic test came back positive and a molecular diagnosis for FHH type 1 was made after discovering the presence of a mutation in the calcium-sensing receptor gene (CASR). There was an amino acid substitution of proline to leucine (termed p.Pro55); a pathogenic variant recognised as a cause of FHH type 1.

DISCUSSION:

Familial Hypocalciuric Hypercalcaemia (FHH) is a rare cause of hypercalcaemia. It is an autosomal dominant condition which manifests from loss-of-function mutations in the CASR gene.¹ The typical biochemical picture includes mild hypercalcaemia, which is associated with hypermagnesemia and hypophosphatemia. Similarly to hyperparathyroidism, there is an inappropriately normal or mildly raised Parathyroid hormone level. However, the important distinction in FHH is that there is reduced urinary calcium excretion. Patients are usually asymptomatic and the hypercalcaemia tends to be detected incidentally. The diagnosis should be suspected in any patients with a strong family history of hypercalcaemia.

This is an exceptional case where the patient, who has had FHH confirmed after genetic testing, has been symptomatic with recurrent renal stones and osteopenia (see figure 3).

Figure 3.



Region	Area[cm ²]	BMC[g]	BMD[g/cm ²]	T-score	FR (Peak Reference)	Z-score	AM (Age Matched)
Neck	5.12	3.91	0.763	-0.8	90	0.1	101
Troch	10.10	6.25	0.619	-0.8	88	-0.3	96
Inter	18.82	19.80	1.052	-0.3	96	0.0	101
Total	34.04	29.96	0.880	-0.5	93	0.0	101
Ward's	1.13	0.69	0.607	-1.1	83	0.4	108

Ward's Triangle is the earliest site to show bone demineralisation on DEXA scans. This patient's T-score of -1.1 demonstrates osteopenia.

Vargas-Poussou et al² detected 101 mutations in the CASR gene. They compared the phenotypes of patients with genetically proven FHH to those with primary hyperparathyroidism. The article concluded that the risk of confusion between FHH and primary hyperparathyroidism is high², highlighting the need for genetic testing. Roldán et al³ presented 3 case reports from one family with FHH and reviewed the topic, suggesting that FHH is more prevalent than originally anticipated, and there is often a family history. As highlighted in our case, four other family members of different generations were also noted to have hypercalcaemia.

CONCLUSION:

Patients with FHH are known to be asymptomatic. We have demonstrated an unusual case of symptomatic FHH, with associated end-organ damage. The possibility of dual pathology should be explored. Thus the case has been referred to a tertiary centre for further investigation.

References:

1. A Practical Approach to Hypercalcaemia - May 1, 2003 - American Family Physician. <https://www.aafp.org/afp/2003/0501/p1959.html>
2. Vargas-Poussou R, Mansour-Hendili L, Baron S, et al. Familial hypocalciuric hypercalcaemia types 1 and 3 and primary hyperparathyroidism: similarities and differences. J Clin Endocrinol Metab. 2016;101:2185-2195.
3. Olivar Roldán J, Pavón de Paz I, Iglesias Bolaños P, Montoya Álvarez T, Fernández Martínez A, Monereo Megías S. Familial hypocalciuric hypercalcaemia: review of three cases. Endocrinol Nutr. 2008;55:267-269.