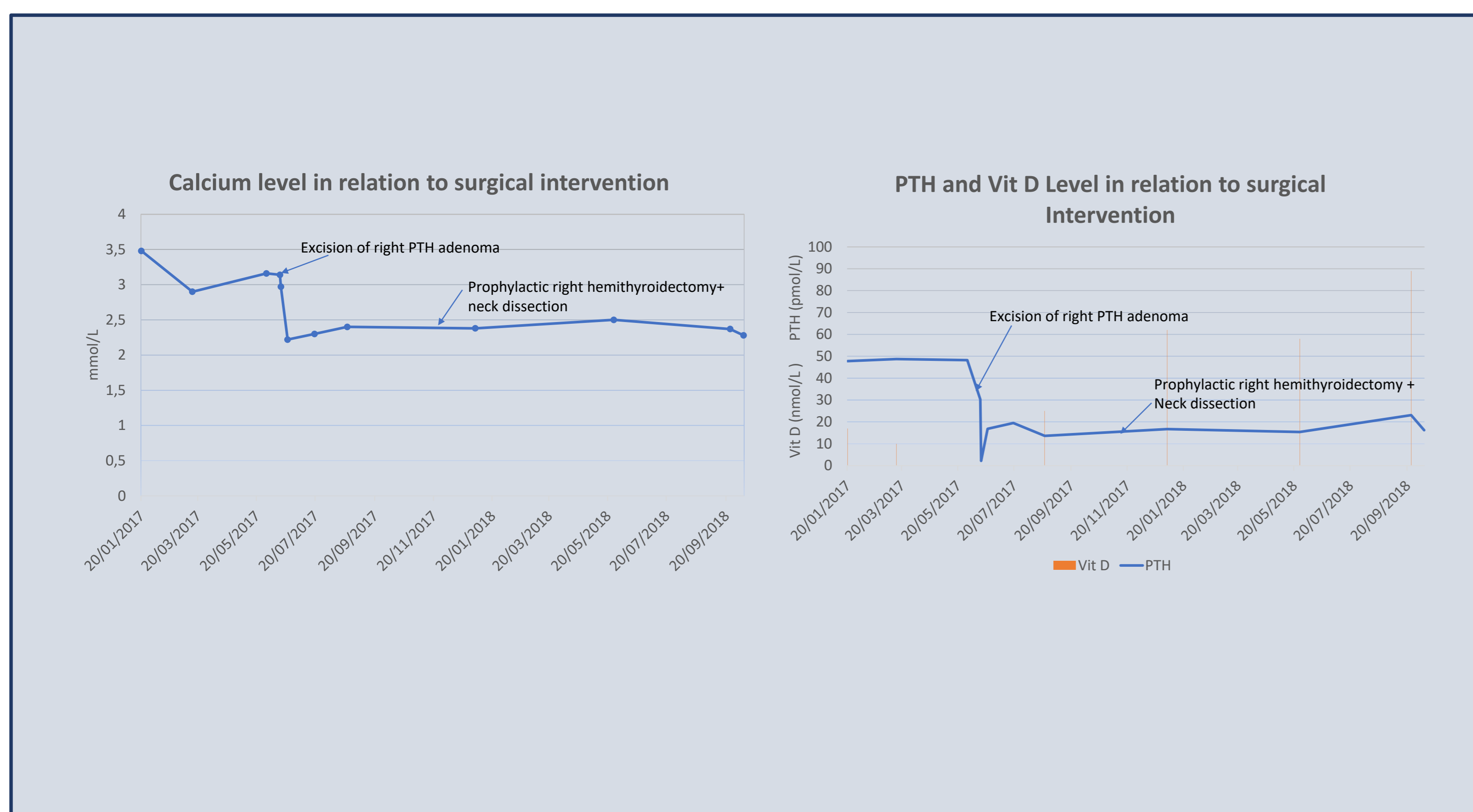


PTH Elevation Post Excision of Parathyroid Carcinoma – Postoperative Phenomenon or Evidence of Disease Spread?

AUTHORS: Dr Ei Thuzar Aung, Dr Helen Leitch-Devlin, Dr Nyi Htwe – Department of Endocrinology and Diabetes, Pilgrim Hospital Boston, ULHT

INTRODUCTION

- Parathyroid carcinoma is a rare endocrine neoplasm
- PTH rise post parathyroid adenoma resection in the absence of recurrent disease, although not common, has been well described in previous publications as a metabolic phenomenon
- We report a case of a 71 year old lady with Parathyroid Carcinoma who had persistent PTH elevation following parathyroidectomy with normal calcium and no evidence of recurrence after a year of follow up
- We set out to investigate the significance of raised PTH post Parathyroid Carcinoma resection via a Literature Review



CASE REPORT

- 71 year old presented with abdominal pain, constipation and 3 stone weight loss. Recurrent admissions with complications of hypercalcaemia over following weeks.
- Investigations: Adj Ca 3.42, PTH 47.8, Vitamin D 17, Ultrasound Neck showed 3cm right lower pole parathyroid adenoma, SESTAMIBI also in keeping with right lower parathyroid adenoma. DEXA scan showed osteoporosis with T-score of -2.9 at the femoral neck.
- Right inferior parathyroidectomy performed – intra-operatively parathyroid mass suspicious of carcinoma, confirmed with histology showing incomplete excision
- Post-operatively Adj Calcium and PTH both normalised initially

Subsequent Events:

- 1 week post-op PTH levels rose to 19.8
- Went on to have Right hemi-thyroidectomy and right neck dissection level II, IV and VI.
- Despite normal calcium and a replaced vitamin D, PTH has remained elevated between 13.1 and 33
- No evidence of recurrence/residual disease found on SESTAMIBI and whole body PET scan
- Patient remains free of recurrence 1 year later although PTH remains elevated

LITERATURE REVIEW

Objectives:

- To investigate the significance of raised PTH post Parathyroid Carcinoma resection via a Literature Review

Methods:

- Literature searches of EMBASE and Pubmed Databases using keywords 'parathyroid carcinoma' and 'PTH elevation'. 15 relevant case studies and a retrospective analysis of 17 patients were identified from 235 results. Initial presentation, initial management, PTH and calcium levels, subsequent investigations and subsequent management/outcome were compared

Findings:

- Of 15 case studies with PTH rise post treatment for parathyroid carcinoma, 10 had evidence of recurrence
- In all 10 of these cases, the calcium level was also found to be raised
- One case showed raised PTH with low calcium and no evidence of disease recurrence which was attributed to 'hungry bones' syndrome
- Two cases showed persistently mildly raised PTH and normal calcium with no evidence of recurrence
- In the last 2 cases both PTH and calcium gradually rose post operatively but no localisation seen on imaging.
- Diagnostic modalities used to positively identify recurrence varied and included MRI, Ultrasound, CT, PET-CT, SESTAMIBI and venous sampling
- The retrospective analysis of 17 cases of parathyroid carcinoma showed for all patients who died as a consequence of parathyroid cancer, none had normalisation of PTH levels at follow-up

CONCLUSION

- The most common cause of raised PTH post resection of parathyroid carcinoma is residual or recurrent disease
- However in our patient and 4 cases in the literature search, no evidence of residual or recurrent disease was found
- The phenomenon of persistent PTH elevation without residual disease is well described in the context of parathyroid adenoma and has been attributed to vitamin D deficiency and 'hungry bones' syndrome
- There is much less evidence in parathyroid carcinoma and PTH is often used as a surrogate tumour marker
- In our case and 2 from the literature, the calcium level remained normal despite elevated PTH which has previously been shown to support lack of residual disease in adenomas
- There is no standardised diagnostic modality to identify or exclude recurrence of parathyroid carcinoma
- We hypothesise there may be a metabolic phenomenon post parathyroid carcinoma resection presenting with persistent PTH rise with a normal calcium level**
- However, unlike with parathyroid adenoma, this is a rare entity so patients need thorough investigation for recurrence and close follow- up**

REFERENCES

Parathyroid carcinoma: A report of six cases with a brief review of the literature. *Oncol Lett.* 2015, Hypercalcaemic encephalopathy due to metastatic parathyroid carcinoma. *BMJ Case Reports.* 2017, Sorafenib treatment improves refractory hypercalcaemia in a patient with metastatic parathyroid carcinoma: A case report *Endocrine Society Annual Meeting 2014*, Successful palliation of metastatic parathyroid carcinoma with denosumab and microwave and radiofrequency ablation *Endocrine Society Annual Meeting 2014*, Parathyroid carcinoma-Initial presentation, management and follow-up in three cases. *NuklearMedizin. Conference 2011*, A case of bone pain in a patient with previous thyroid cancer *Endocrine Society Annual Meeting 2015*, Parathyroid carcinoma with postoperative prolonged hypocalcemia in a patient with chronic renal failure. *Journal of the Formosan Medical Association 1996*, Eucalcaemic PTH elevation after parathyroidectomy for primary hyperparathyroidism *Endocrine Society Annual Meeting 2013*, Challenges and pitfalls in the management of parathyroid carcinoma: 17-year follow-up of a case and review of the literature *Hormone Cancer 2018*, Refractory hypercalcaemia secondary to parathyroid carcinoma: response to high-dose denosumab *European journal of endocrinology 2014*, . Atypical manifestation of parathyroid carcinoma with late-onset distant metastases *Endocrinology, Diabetes and Metabolism 2017*, Clinicopathological phenotype of parathyroid carcinoma: therapeutic and prognostic aftermaths *Chirurgia 2015*, Parathyroid carcinoma, a rare cause of primary hyperparathyroidism *BMJ 2014*, Parathyroid carcinoma and oxyphil parathyroid adenoma: an uncommon case of misinterpretation in clinical practice *Endocrine Journal 2013*