

Thyroid ¹⁸F-FDG-PET Positivity; pattern and implications

W. Majeed, S Shalet, H Doran, S Ghattamaneni, SCO Taggart, A. Mukherjee

Salford Royal NHS Foundation Trust

email: waseemmajeed@doctors.org.uk



Introduction

A thyroid incidentaloma is defined as a newly detected thyroid abnormality by radiological imaging performed for an unrelated purpose¹. Modalities include ultrasound, CT, PET-CT and MRI.

The use of ¹⁸F-FDG-PET/CT (PET) staging for a variety of malignancies has increased in recent years. A rise in detection of incidental thyroid lesions creates a novel diagnostic challenge. Multiple studies have suggested that not all such incidentalomas are appropriately followed up.¹⁻³

The incidence of thyroid incidentalomas detected by PET ranges from 0.2% to 8.9%; a pooled analysis of studies showed an incidence of 2.46%.¹ The most common uptake patterns are focal and diffuse.^{1,4}

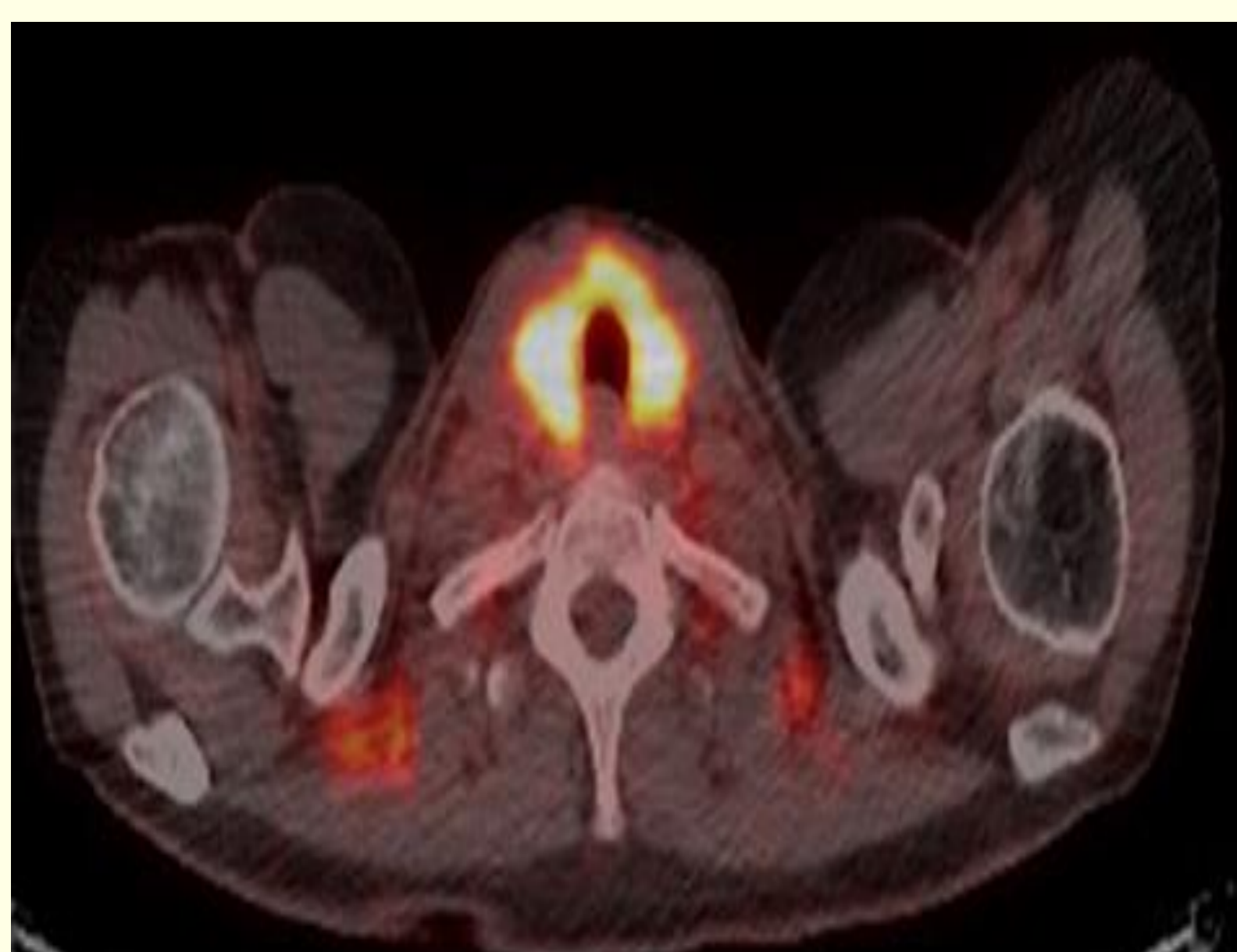
We present four cases of thyroid PET positivity. We discuss patterns of uptake and their diagnostic and management implications.

Cases

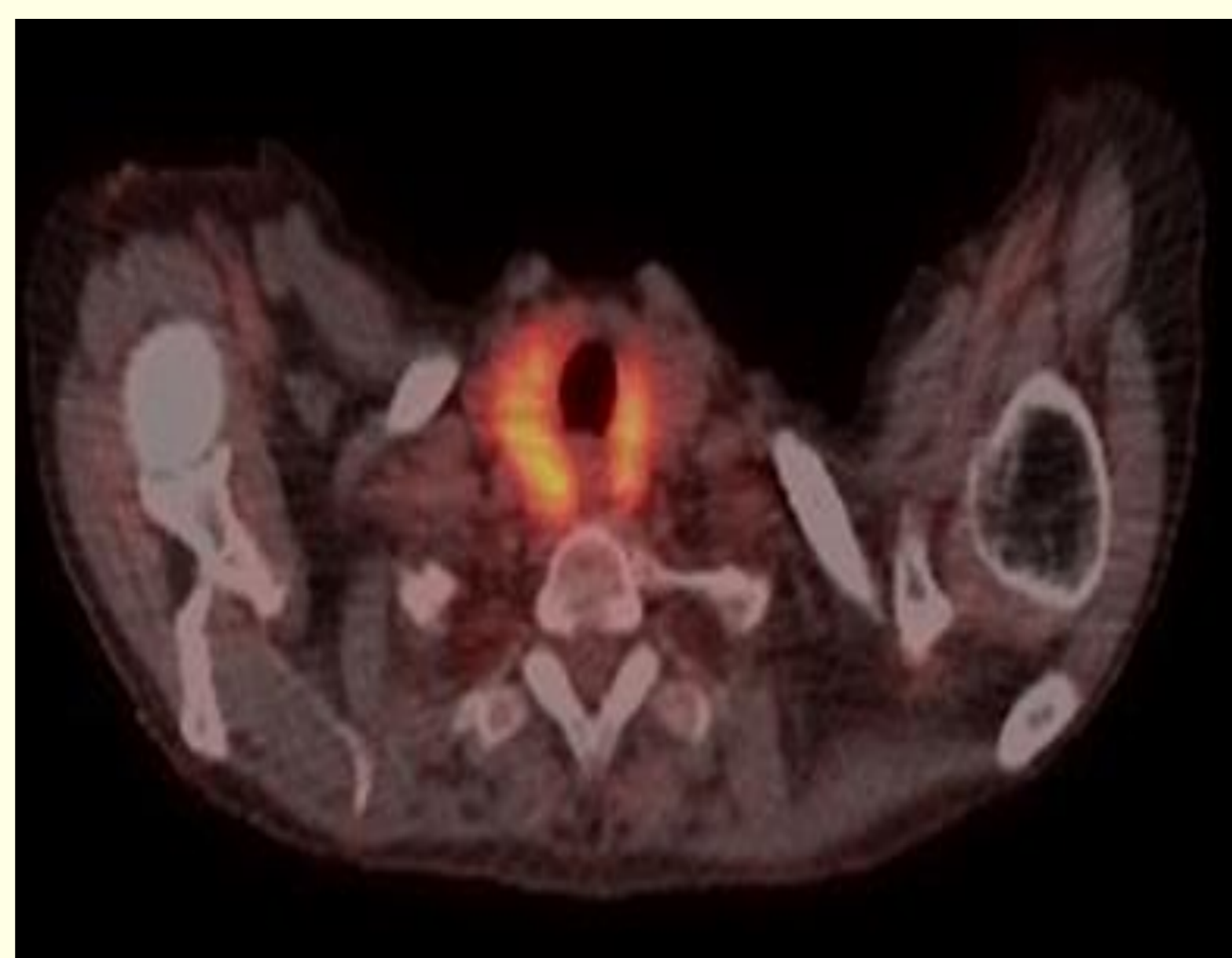
- **Case 1:** A 62-year-old lady with pulmonary adenocarcinoma on contrast CT-Thorax had incidental diffuse thyroid PET uptake on staging. There was no previous history of thyroid disease. Biochemistry revealed a self limiting TSH-rise and thyroid peroxidase antibody positivity.
- **Case 2:** A 77-year-old lady had an incidentally discovered lung lesion and 2 thyroid nodules on CT Thorax. PET staging showed patchy thyroid uptake. History of treated autoimmune hypothyroidism was noted. Thyroid biochemistry was normal on replacement levothyroxine.
- **Case 3:** A 62-year-old gentleman with oesophageal adenocarcinoma had PET staging which showed focal uptake within a right thyroid nodule. He had no pre-existing thyroid disease. Thyroid biochemistry was normal.
- **Case 4:** A 42-year-old lady with incidental anterior mediastinal nodules on CXR had a staging CT which revealed a thyroid isthmus nodule showing focal PET-positivity. Other lung nodules were classed as benign. There was no history of thyroid disease and thyroid biochemistry was normal.

¹⁸F-FDG-PET Imaging

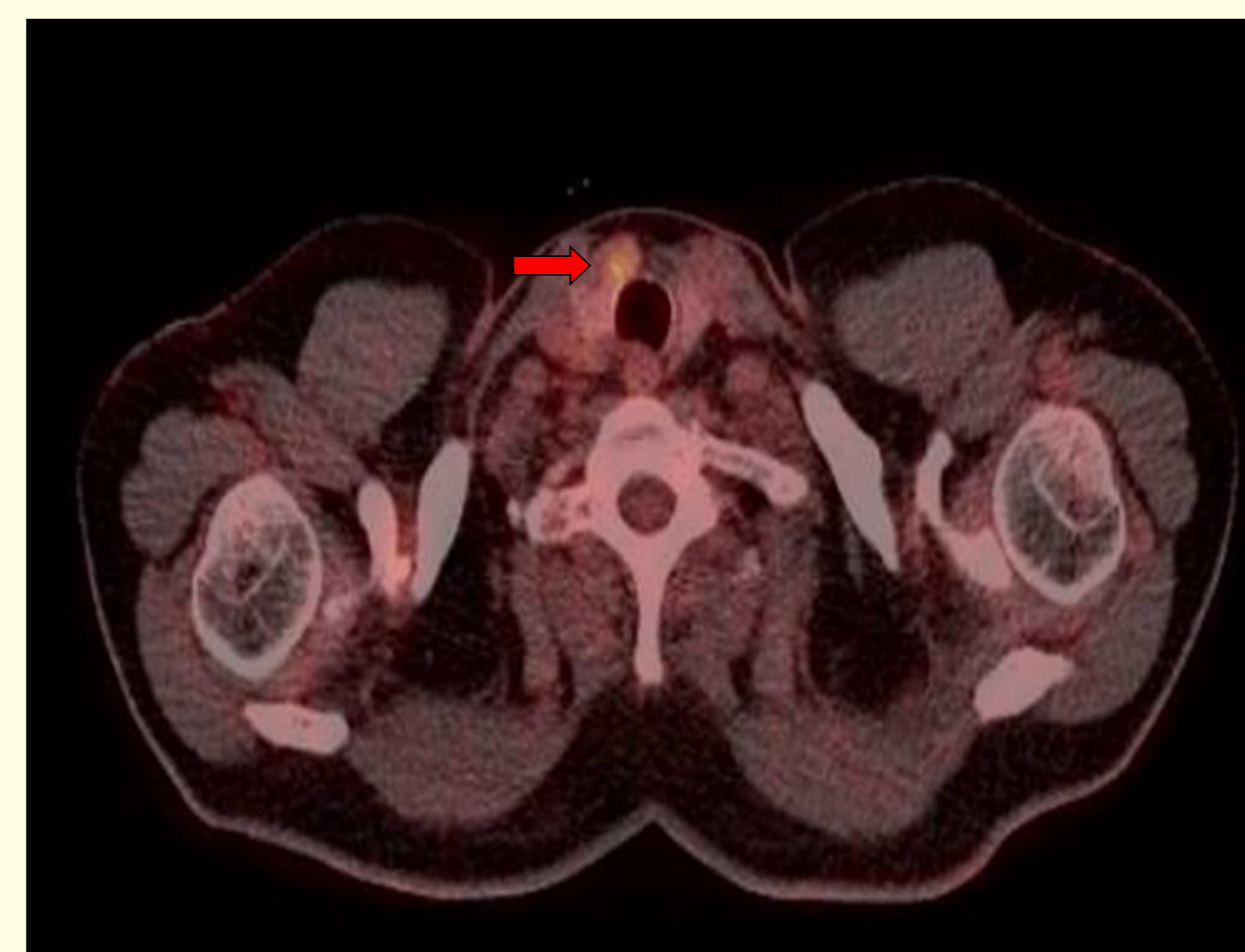Case 1
Diffuse Uptake



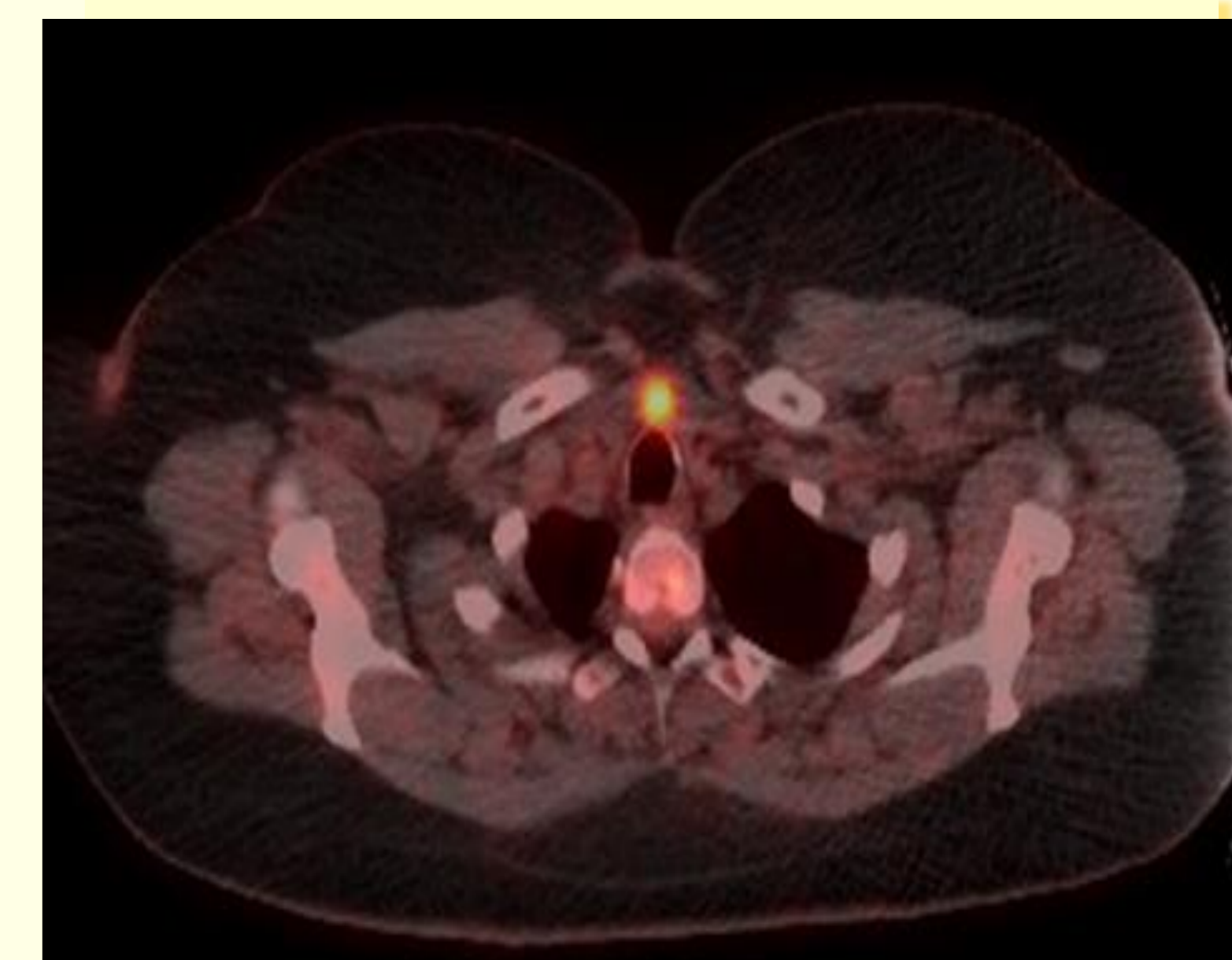
Case 2
Patchy Uptake



Case 3
Focal Uptake



Case 4
Focal Uptake



Outcomes

Case 1: Thyroid ultrasound showed evidence of a multinodular goitre. Appearances were classed as U2 and therefore benign. Fine needle aspiration for cytology (FNAC) was not indicated. The likely explanation for diffuse PET-uptake was a transient self-limiting contrast-induced thyroiditis.

Case 2: Thyroid ultrasound showed evidence of a nodular thyroid (U2) with mild thyroiditis in keeping with pre-existing autoimmune thyroid disease. FNAC was not performed. The lung lesion was diagnosed as a benign bronchogenic cyst.

Case 3: Thyroid ultrasound revealed a multinodular goitre with a dominant U3 nodule right of the isthmus. FNAC suggested evidence of atypical features concerning for a follicular variant of papillary thyroid carcinoma. The patient had a right hemi-thyroidectomy; subsequent histological assessment confirmed the diagnosis. He also underwent successful surgical resection of his oesophageal carcinoma prior to thyroid surgery.

Case 4: Thyroid ultrasound showed a U3 nodule right of isthmus. FNAC showed Thy3f cytology. She underwent a right thyroid lobectomy; histological assessment revealed a benign Hurthle Cell adenoma.

Discussion

There remains a need to develop a standardised approach to investigate and manage all thyroid incidentalomas. The rate of malignancy in PET detected thyroid incidentalomas is approximately 1 in 3.^{1,5} The most commonly discovered malignancy in this cohort is papillary thyroid carcinoma.¹

Importantly, focal thyroid uptake is more suspicious for malignancy while diffuse uptake is suggestive of benign aetiology such as thyroiditis.^{1,3}

At our tertiary centre, all referred thyroid incidentalomas are investigated within the 2 week rule with a clinical assessment and thyroid ultrasound. Ultrasound classification determines the need for FNAC. Consequent management is determined by MDT discussion and guidelines for management of thyroid cancer issued by the British Thyroid Association in 2014.⁶

In conclusion, thyroid incidentalomas picked up on PET have malignant potential. A focussed and accelerated strategy as suggested above, will ensure prompt diagnosis and effective treatment. This is of paramount importance especially in patients who are on management pathways for other malignancies.

References

1. Bertagna F, Treglia G, Piccardo A, Giubbini R. Diagnostic and clinical significance of F-18-FDG-PET/CT thyroid incidentalomas. *J Clin Endocrinol Metab.* 2012;97(11):3866-75
2. Brindle R, Mullan D, Yap BK, Gandhi A. Thyroid incidentalomas discovered on positron emission tomography CT scanning - Malignancy rate and significance of standardised uptake values. *Eur J Surg Oncol.* 2014;40(11):1528-32
3. Salvatori M, Melis L, Castaldi P, Maussier ML, Rufini V, Perotti G, et al. Clinical significance of focal and diffuse thyroid diseases identified by 18F-fluorodeoxyglucose positron emission tomography. *Biomed Pharmacother.* 2007;61(8):488-93.
4. Makis W, Ciarallo A. Thyroid Incidentalomas on 18F-FDG PET/CT: Clinical Significance and Controversies. *Molecular Imaging Radionucl Ther.* 2017;26(3):93-100
5. Shie P, Cardarelli R, Sprawls K, Fulda KG, Taur A. Systematic review: prevalence of malignant incidental thyroid nodules identified on fluorine-18 fluorodeoxyglucose positron emission tomography. *Nucl Med Commun [Internet].* 2009;30(9):742-8
6. Perros P, Colley S, Boelaert K, Evans C, Evans R, Gerrard G, et al. Guidelines for the management of thyroid cancer. *Clin Endocrinol (Oxf) [Internet].* 2014;81(Supplement 1 July 2014):1-136