


Severe thyroid-associated orbitopathy manifesting two years post total thyroidectomy for follicular carcinoma variant of the thyroid

Rozana Ramli, Fausto Palazzo, Stephen Robinson, Vicky Lee
Division of Diabetes, Endocrinology & Metabolic Medicine, St Mary's Hospital and Hammersmith Hospital
Department of Ophthalmology, Western Eye Hospital
Imperial College Healthcare NHS Trust, UK



CASE PRESENTATION

- We present a case of severe thyroid-associated orbitopathy in a 44-year-old man with metastatic follicular carcinoma of the thyroid.
- He presented with a neck lump, and following further investigations, underwent a hemithyroidectomy followed by a completion thyroidectomy.
- Histology of the thyroid confirmed widely invasive follicular carcinoma of Hurthle cell type with foci of vascular invasion (pT3 Nx Mx).
- He received radioactive iodine ablation therapy (3.7 GBq), and continued on suppressive Levothyroxine therapy.

PROGRESS

- He remained clinically stable for 24 months, when he was discovered to have relapsed (thyroglobulin 290 ug/L, thyroglobulin antibody <20 IU/ml).
- Cross-sectional imaging and a diagnostic Iodine-123 imaging showed active disease in subcarinal and mediastinal lymph nodes, liver, lungs and skeletal system.
- Therapeutic radioactive iodine (5.5 GBq) was administered, with variable uptake within the thyroid bed and paratracheal region, anterior mediastinum and liver.

DEVELOPMENT OF THYROID-ASSOCIATED ORBITOPATHY

- Five months following his relapse, he reported a three-month history of orbital discomfort and visual disturbances.
- Clinical examination, biochemistry (TSH receptor antibody > 30 unit/ml) and magnetic resonance imaging were consistent with features of moderately active thyroid-associated orbitopathy with no sight threatening complications (Picture A).
- There is no personal or family history of autoimmune thyroid or other autoimmune disease.

TREATMENT OF THYROID-ASSOCIATED ORBITOPATHY

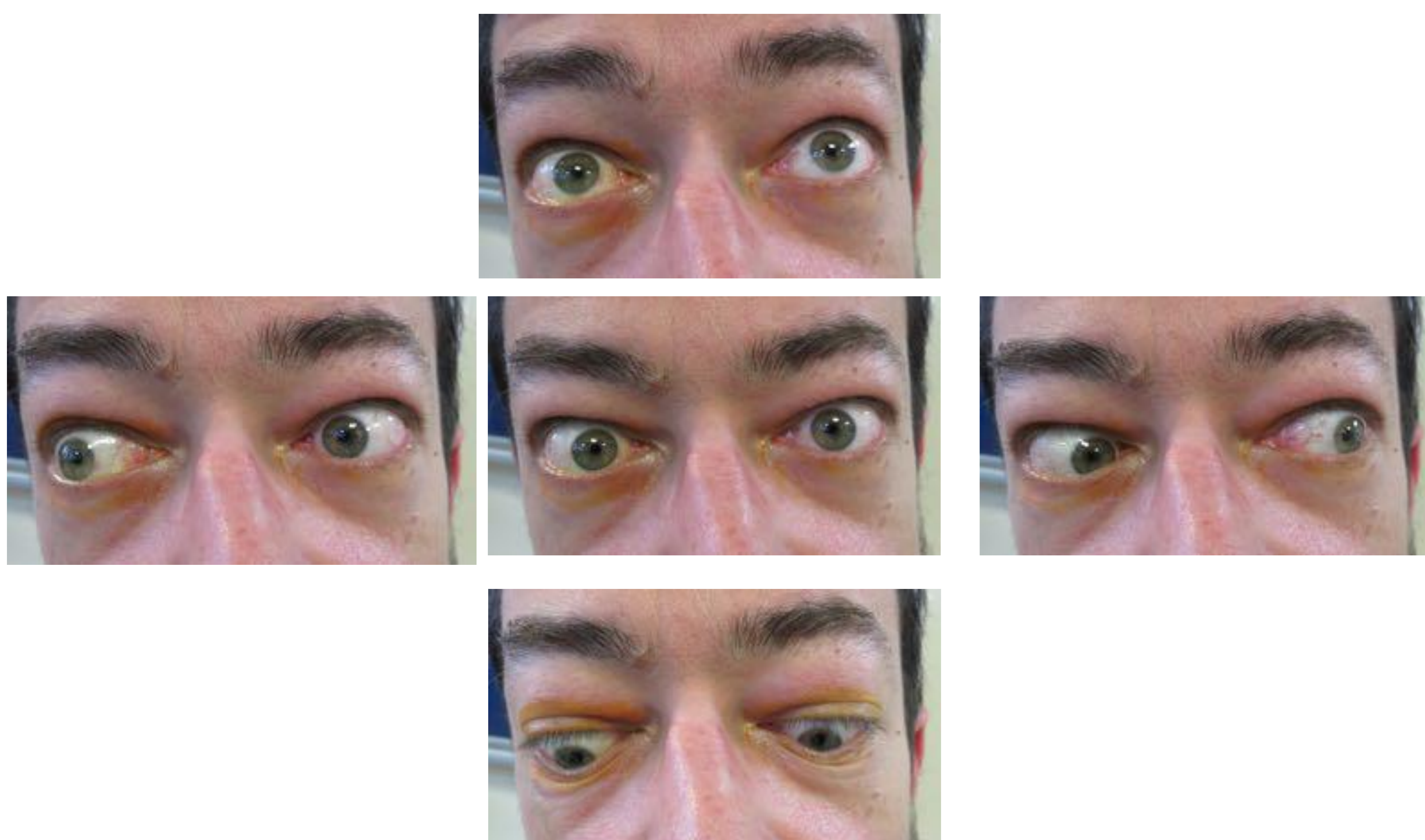
- He was commenced on a 12-week course of pulsed intravenous Methylprednisolone and local orbital floor steroids with only slight improvement.
- He continued receiving concurrent palliative treatment for his metastatic disease including Zoledronic Acid, Sorafenib (tyrosine kinase inhibitor) and single fraction radiotherapy to bone metastases.
- As he continued to have severe restriction of upward gaze and bilateral marked lid retraction, he received external beam orbital radiotherapy (20Gy in 10 fractions).

CLINICAL OUTCOME

- His metastatic disease remained active and he died 17 months after his relapse.

CONCLUSION

- We postulate an unusual and large antigen load precipitating thyroid-associated orbitopathy in the absence of endogenous TSH production following radioactive iodine therapy and prior to the use of an immune checkpoint inhibitor (Sorafenib)



Picture A: Thyroid-associated orbitopathy with severe restriction of upward gaze and bilateral lid retraction in our patient.