

# Case Report: Cushing's Disease

**Katy Chisenga**

Medical Student, University of Cambridge

(E-mail: [kmc48@cam.ac.uk](mailto:kmc48@cam.ac.uk))

**Introduction:** Cushing's syndrome is caused by an extended exposure to increased levels of endogenous or exogenous glucocorticoids. It is a syndrome that can be extremely challenging to diagnose as many symptoms and signs are also indications of other disease processes.

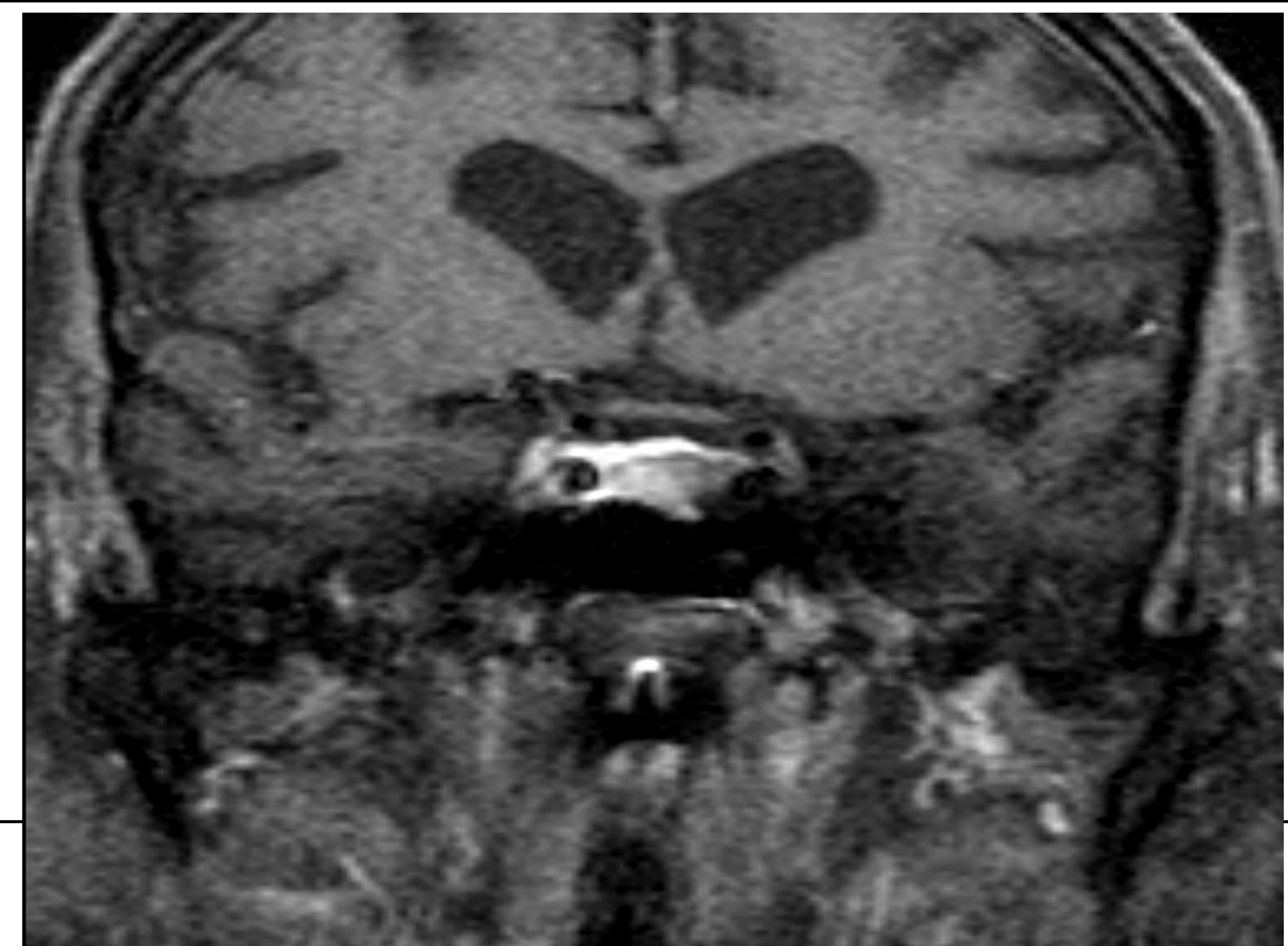
**Case Presentation:** A 76 year old man presented with a six month history of immobility and falls. Progressive proximal muscle weakness was noted and the patient was sent for rehabilitation. The patient's past medical history consisted of Type 2 Diabetes Mellitus, hypertension, congestive cardiac failure, combined B12 and folate deficiency, a urinary tract infection, a long term suprapubic catheter due to urinary retention and a myocardial infarction in 1991 that was medically managed. His drug history consisted of metformin, gliclazide, amiloride, aspirin, folic acid, hydroxycobalamin, ranitidine and paracetamol PRN. With respect to his social history he is a former HGV driver and prison officer, smoked four cigarettes a day until 1990, drinks four pints of alcohol a week with no history of excess, and lives at home with his wife.

## Investigations

24 urinary free cortisol: **206** nmol/24 hr (0-146/24hr)  
 Overnight DST: **1588** nmol/L  
 Low dose dexamethasone suppression test: **1131** nmol/L (<50 nmol/L)  
 ACTH **139** pmol/L

## Diagnosis

The results suggested ACTH-dependent Cushing's. Following MRI a left-sided pituitary adenoma was diagnosed thus confirming Cushing's disease rather than an ectopic secretion.



## Management

The results suggested ACTH-dependent Cushing's. Following MRI a left-sided pituitary adenoma was diagnosed thus confirming Cushing's disease rather than an ectopic secretion. The patient was prescribed metyrapone and a cortisol day series was carried out.

	1/11/2016 pre-treatment	4/11/2016 (250mg metyrapone qds)
09:00	1301	2071
11:00	1425	1520
13:00	1358	1960
17:00		1580

Following this the patient was prescribed rescue dexamethasone and was to be worked up for transphenoidal surgery. However due to worsening shortness of breath and peripheral oedema as a result of congestive cardiac failure the hypercortisolaemia is being managed medically as an inpatient with progression to neurosurgery should he stabilise.

**Conclusion:** Cushing's disease is a rarity that can be difficult to diagnose due to the significant number of varied pathologies indicated by its signs and symptoms. This is an interesting case of Cushing's disease as the levels of cortisol measured in the patient were incredibly high.