

AN UNUSUAL CAUSE OF STROKE IN A YOUNG PERSON

Dana Ershaid¹ Nadal aker² Khalid Ali¹ Kofi Obuobie¹

1-Royal Gwent Hospital (UK) , 2-Decatur Memorial Hospital (USA)

Background

Thyrotoxicosis is a common disease with associated excess circulating thyroid hormones presenting with a variety of symptoms. There is increased risk of acute ischaemic stroke both arterial and venous. Previous reports have shown strong links between the different thyroid diseases and cerebrovascular disease(1). In this case report, we discuss various aspect of stroke in the context of thyrotoxicosis.

Case Presentation

A 24-year old Caucasian woman was admitted with a 3-day history of intermittent word finding difficulties. She also complained of numbness of the right side of her mouth and face preceded by mild left sided headache.

She had a background history of uncontrolled Graves' Thyrotoxicosis mainly due to poor adherence with her antithyroid drugs. The management plan agreed with the Endocrinologist was to offer radiodine when adequate control was established on Carbimazole. She smoked 10 cigarettes a day for the past 11 years and was a teetotaler. She has been on the combined contraceptive pill up for one week prior to presentation.

On examination, she had a pulse of 110 beats per minute with a normal blood pressure and a blood glucose of 7 mmol/l .She had mild expressive dysphasia and right facial droop, no other focal neurological deficit .

Investigations

Thyroid function tests showed uncontrolled thyrotoxicosis with a free T4 of 22.5pmol/L (9-25 pmol/L) and TSH <0.01 mU/L (0.4-4.0 mU/L).

ECG showed sinus tachycardia.

CT and MRI Scans of the brain demonstrated left frontal lobe acute infarct (Figure 1), carotid Doppler did not confirm evidence of extracranial carotid disease, transthoracic echocardiogram did not reveal any structural heart disease and a 24 hours holter monitor showed sinus tachycardia but no paroxysmal atrial fibrillation..

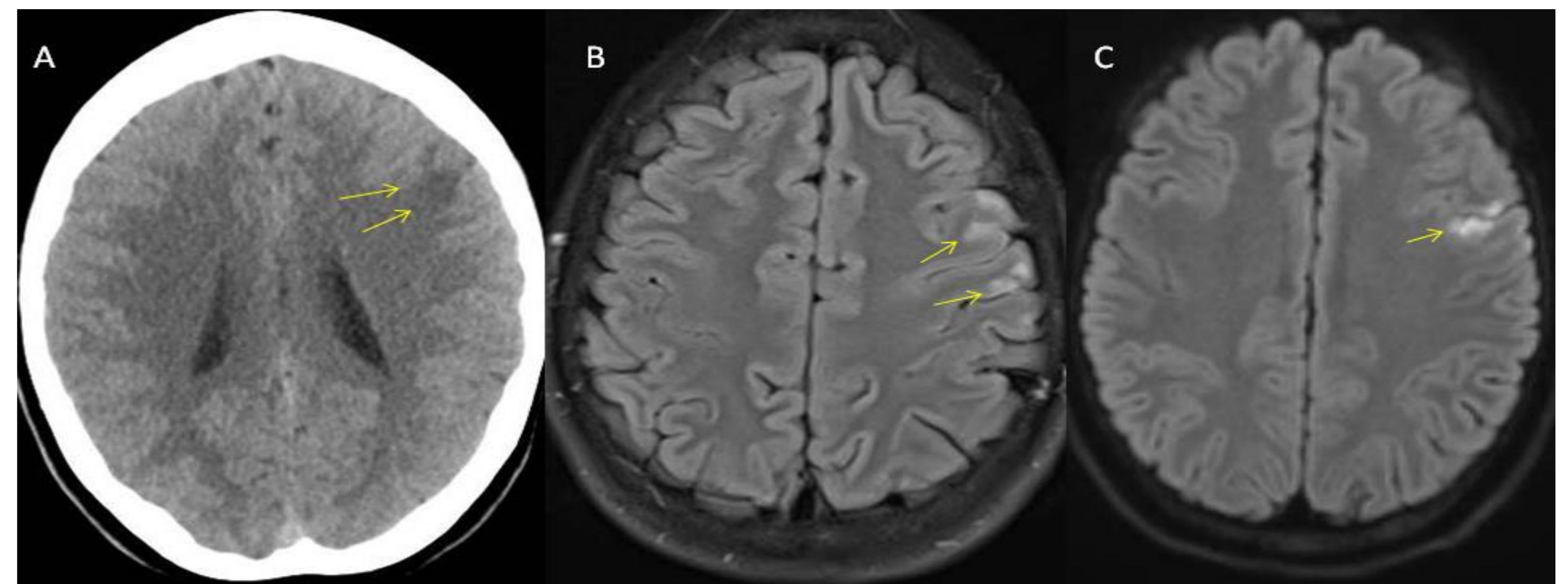


Figure 1 (A-C): A, uncontrasted CT brain showing hypodense lesion in the left frontal lobe. B: M brain FLAIR sequence showing high signal abnormality affecting the left middle cerebral artery territory. C: Diffusion weighted sequence showing an area of restricted diffusion of the left middle cerebral artery distribution indicating acute infarction.

Management

The overall impression was that her acute cerebral infarction was likely cardioembolic in origin, probably due to thyrotoxicosis-induced paroxysmal atrial fibrillation..

The decision was taken to anticoagulate with Apixaban. She was also treated with Carbimazole and Propranolol. She made a good recovery and was discharged home. With a plan for Radioactive iodine in the future.

Discussion

Hyperthyroidism is known to induce a hypercoaguable state (1-3). Whether patients with thyrotoxic atrial fibrillation should receive anticoagulation therapy is not well defined by specific randomized trials(2) . Whilst atrial fibrillation has never been confirmed in our patient. Paroxysmal atrial fibrillation has been shown to account for 12% of cryptogenic strokes in the Crystal AF study using prolonged monitoring (4). The same results were replicated in the EMBRASE trial (5).

Hence it is reasonable to consider paroxysmal atrial fibrillation as the most likely aetiology of this stroke.

Conclusion

Clinicians should be aware of the risk of stroke in young patients with thyrotoxicosis presenting with unusual neurological symptoms. Other risk factors may influence decision making regarding prophylactic anticoagulation, but use of OCP may need careful consideration in thyrotoxicosis

References :

- 1- Squizzato A, Gerdes V, Brandjes D, Buller H, Stam J. Thyroid Diseases and Cerebrovascular Disease. Stroke. 2005;36(10):2302-2310.
- 2- Min T, Benjamin S, Cozma L. Thromboembolic complications of thyroid storm. Endocrinology, Diabetes & Metabolism Case Reports. 2014
- 3- Verberne H, Fliers E, Prummel M, Stam J, Brandjes D, Wiersinga W. Thyrotoxicosis as a Predisposing Factor for Cerebral Venous Thrombosis. Thyroid. 2000;10(7):607-610.
- 4- Sanna T, Diener H, Passman R, Di Lazzaro V, Bernstein R, Morillo C et al. Cryptogenic Stroke and Underlying Atrial Fibrillation. New England Journal of Medicine. 2014;370(26):2478-2486.
- 5- Gladstone D, Spring M, Dorian P, Panzov V, Thorpe K, Hall J et al. Atrial Fibrillation in Patients with Cryptogenic Stroke. New England Journal of Medicine. 2014;370(26):2467-2477.