

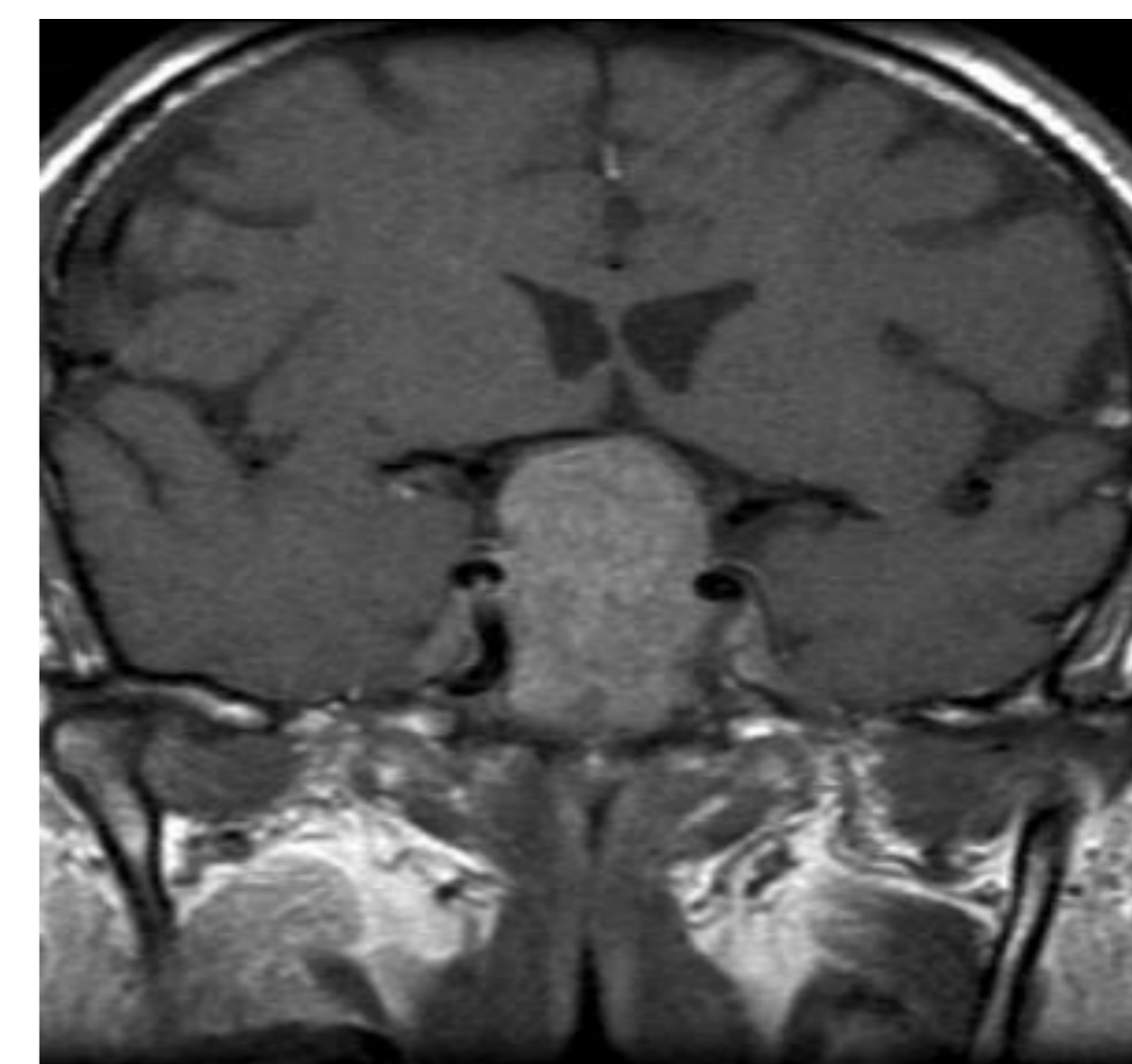
Somatostatin Analogue Use to treat visual field loss in acromegaly newly diagnosed in pregnancy

I. Frizelle, D.J.O'Halloran

1. 11/40 gestation

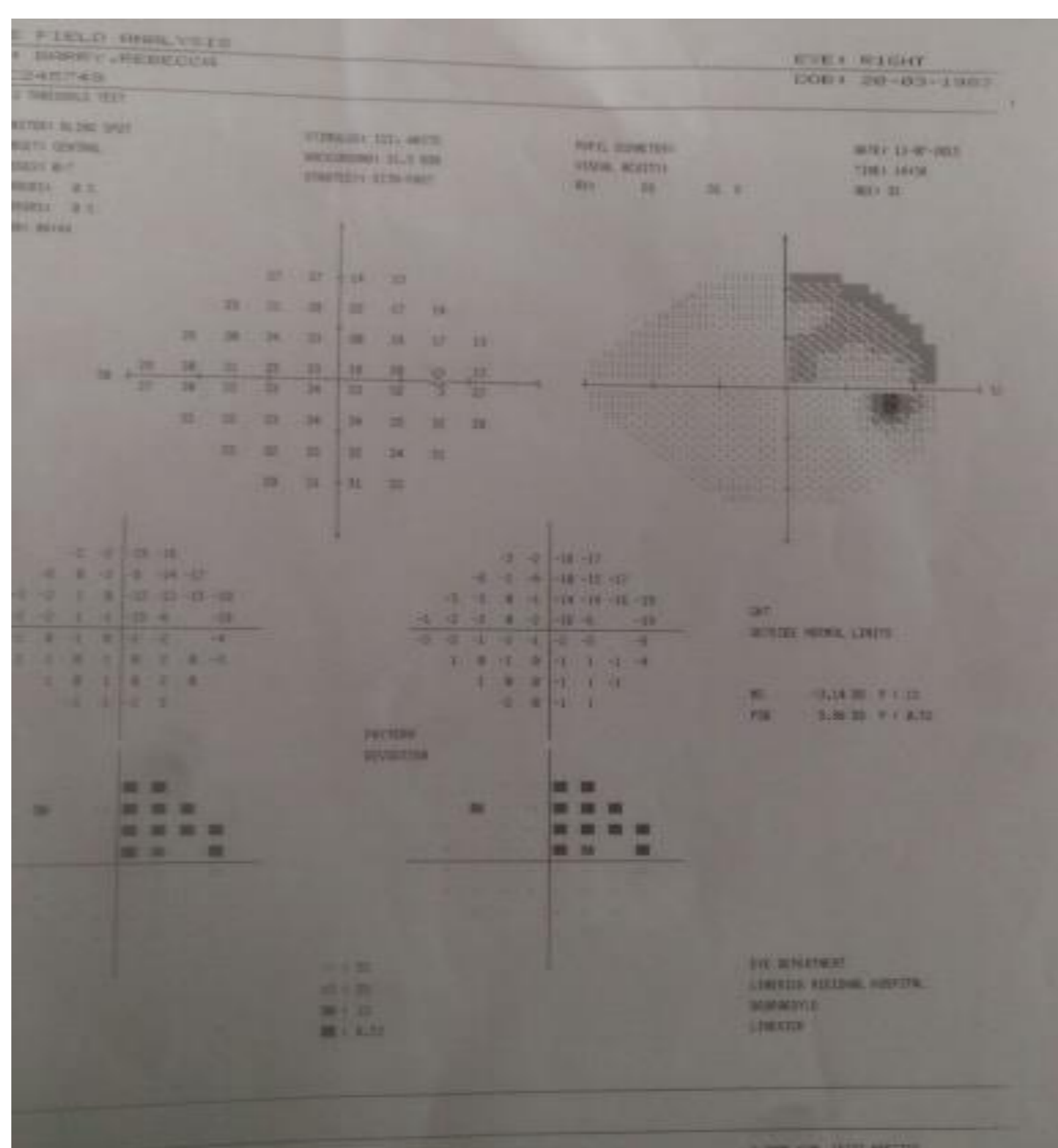
Presenting with headache-
underwent CT brain.
Pituitary mass- MRI pituitary
performed.

2. MRI Pituitary

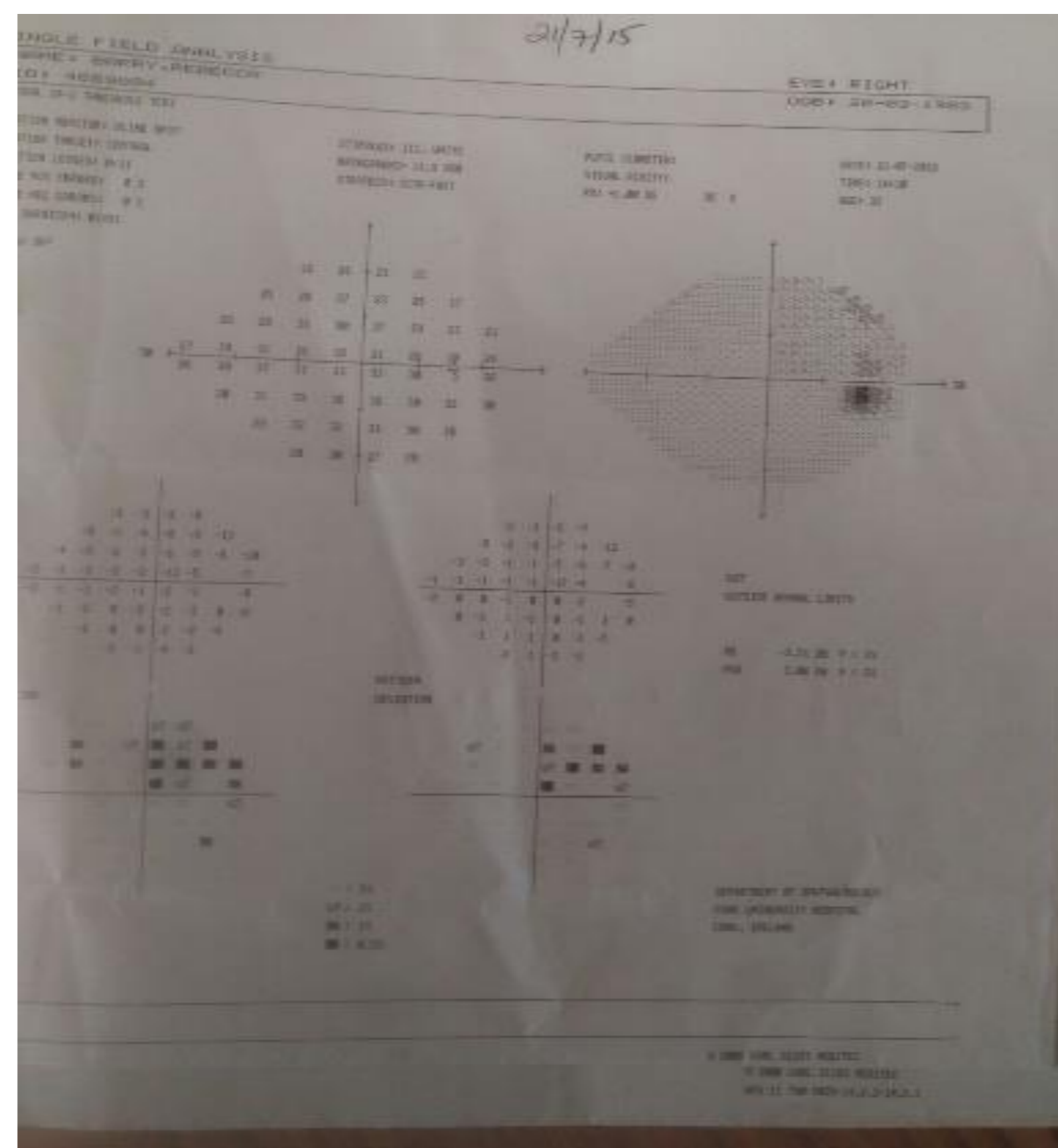


3. Visual field loss. Clinically
acromegalic.

5. Pre:



Post:



Improvement in visual field
2/52 after treatment start date.

4. Patient opted for
medical therapy:
Octreotide 100
micrograms TDS
commenced.

6. Further
deterioration of
visual fields
requiring dose
titration to 200
micrograms tds at
24/40.

7. Foetal growth on 50th
centile throughout
pregnancy
Elective caesarean at
34/40
Uncomplicated
Baby girl 3.2Kg
APGAR score 9

8. Post partum labs
Random GH 9.8
micrograms/L
IGF-1 460 micrograms/L
()age- specific ref range

9. *Points of interest*

- Fertility despite active undiagnosed disease.
- Successful treatment of visual field loss.
- Optimal obstetric outcome.

