

A big price for a little mistake: similar presentations but diverse management of thyroid storm. Use of Extra-Corporeal Membrane Oxygenation (ECMO) in hyperthyroidism related cardiomyopathy

Introduction:

Thyroid storm is a rare endocrine emergency associated with the reported mortality rate ranging from 10 – 20 %. We discuss the management of two cases of thyroid storm with different outcomes. It also showed the successful use of ECMO in the management of severe hyperthyroidism related cardiomyopathy and circulatory collapse.

Case History 1:

A 36 yrs old female ,with known history of Graves disease for last 10 years. She presented through A&E with at-least one week history of shortness of breath ,leg oedema and history of diarrhoea. These symptoms were preceded by viral like illness. She has been on Carbimazole 5 mg on alternate days .She was not very compliant to her medication and did not have thyroid function tests in last two year.

Day 1 : Temperature 38° C, pulse 140/min irregular, BP 132/80, respiratory rate 24/min, O2 saturation 97% on 2litres and CBG 4.7.

Systematic examination: Pulmonary oedema and bilateral leg pitting oedema.

Routine bloods: including LFTs, FBC and CRP were normal .

TFTs:FT4 >100,FT3 35 and TSH < 0.01.

Venous gas: PH 7.38, HCO3 24.3 and Lactate 5.9.

Investigations :Chest x-ray confirmed pulmonary oedema and ECG confirmed fast AF.

Diagnosis :Thyroid storm

Treatment :Intravenous Hydrocortisone 100 mg, Carbimazole 40 mg, Paracetamol, Propranolol 40 mg, Furosemide 40 mg and Digoxin. She was transferred to CCU for close monitoring.

Day2 :she was started on Esmolol infusion due to persistent AF which later on changed to Metoprolol 5 mg intravenously for same reason.

Day4 :Trans thoracic echocardiography on day four showed dilated LV and poor LV systolic function , low normal RV function, bilateral atrial dilatation, EF 40-45 % and severe MR. She was therefore started on spironolactone and ramipril .

Day5 :reverted to sinus rhythm on day five

Day 7 : Discharged on medication :Metoprolol 25 mg TDS,Carbimazole 40 mg OD,Ramipril 2.5 mg OD ,Spironolactone 25 mg OD.

Her follow up echocardiography after six weeks showed improvement EF > 60%. She was offered undergo radioactive iodine therapy as definitive treatment option due to her poor compliance towards regular medication..

Case History 2:

A 53 years old female, with known history of Graves disease stopped taking Carbimazole for a year and didn't have any follow-up for at-least two years . She was admitted through AE with history of shortness of breath, palpitations, weight loss, diarrhoea, symptoms of general malaise and viral like illness for three weeks.

Day 1 : Temperature 38° C, pulse 160-170/min , irregular ,BP of 134/60, O2 saturation of 96 % on 35%, respiratory rate of 28/min

Systemic examination: she was confused, obtunded, agitated, with features of pulmonary oedema.

Routine bloods :Deranged LFTs (Bilirubin 58,ALT 103) , INR 2.1, e-GFR 50 .

TFTs (FT4 >100,ft3 >50 ,TSH<0.01)

Venous gas: PH7.30, lactate 4.8 and BE was -10.

Investigations : The ECG showed AF with heart rate of 140/min and chest x-ray showed bilateral pleural effusions with features suggestive of pulmonary oedema.

Diagnosis :Thyroid storm

Treatment : she was commenced on treatment with Carbimazole 60 mg (via NG), intravenous Hydrocortisone 50 mg, Propranolol 40 mg Furosemide 40mg iv and iv digoxin.

Clinical deterioration within 24hrs with Cardiogenic shock :reduced GCS, AF of 130/min, worsening lactate to 6.2, reduced platelet count of 76 and e-GFR of 22. She immediately was intubated and transferred to ITU for inotropic (adrenaline ,nor-adrenaline and levosimendan) and ventilatory support. The bed side echocardiography showed dilated cardiomyopathy with poor ejection fraction and severe biventricular dysfunction.

Day 2 :Failure to improve on current management lead her transfer to regional tertiary care centre St Guys and Thomas Hospital London for Veno-arterial mode extracorporeal membrane oxygenation (**VA-ECMO**; Figure 1).

Day 5: Her clinical condition improved dramatically on VA-ECMO confirmed by improved LV function on echocardiography and persistent lower ventilatory pressure support.

After two weeks: Following medical optimization she underwent definitive treatment of total thyroidectomy and tracheostomy (for vocal cord paralysis). Post-operative recovery was complicated by sepsis resulting form chest infection , pleural effusion and calculus cholecystitis requiring antibiotics and pleural drainage.

After approximately 3 months: Subsequently, she went on to slow stream rehabilitation and discharged home after approximately 3 months of hospitalization ,after removal of tracheostomy.

Discussion :

We presented two patients with thyroid storm with severe cardiomyopathy. The first patient with relapse of Graves disease presented with thyroid storm, heart failure and atrial fibrillation was recovered with medical management only. The second patient had relapsed Graves' disease complicated with hyperthyroidism-related cardiomyopathy and atrial fibrillation. She developed multi-organ failure with circulatory collapse, necessitating invasive hemodynamic support. She was hemodynamically supported with VA-ECMO and mechanical ventilation, which was successfully weaned off after 4 days. Subsequent echocardiography revealed normalization of the left ventricular ejection function.

Hyperthyroidism-related cardiomyopathy with circulatory collapse is often a fatal condition. Given its highly reversible nature, more aggressive cardio-respiratory support in the form of **VA-ECMO** is warranted.

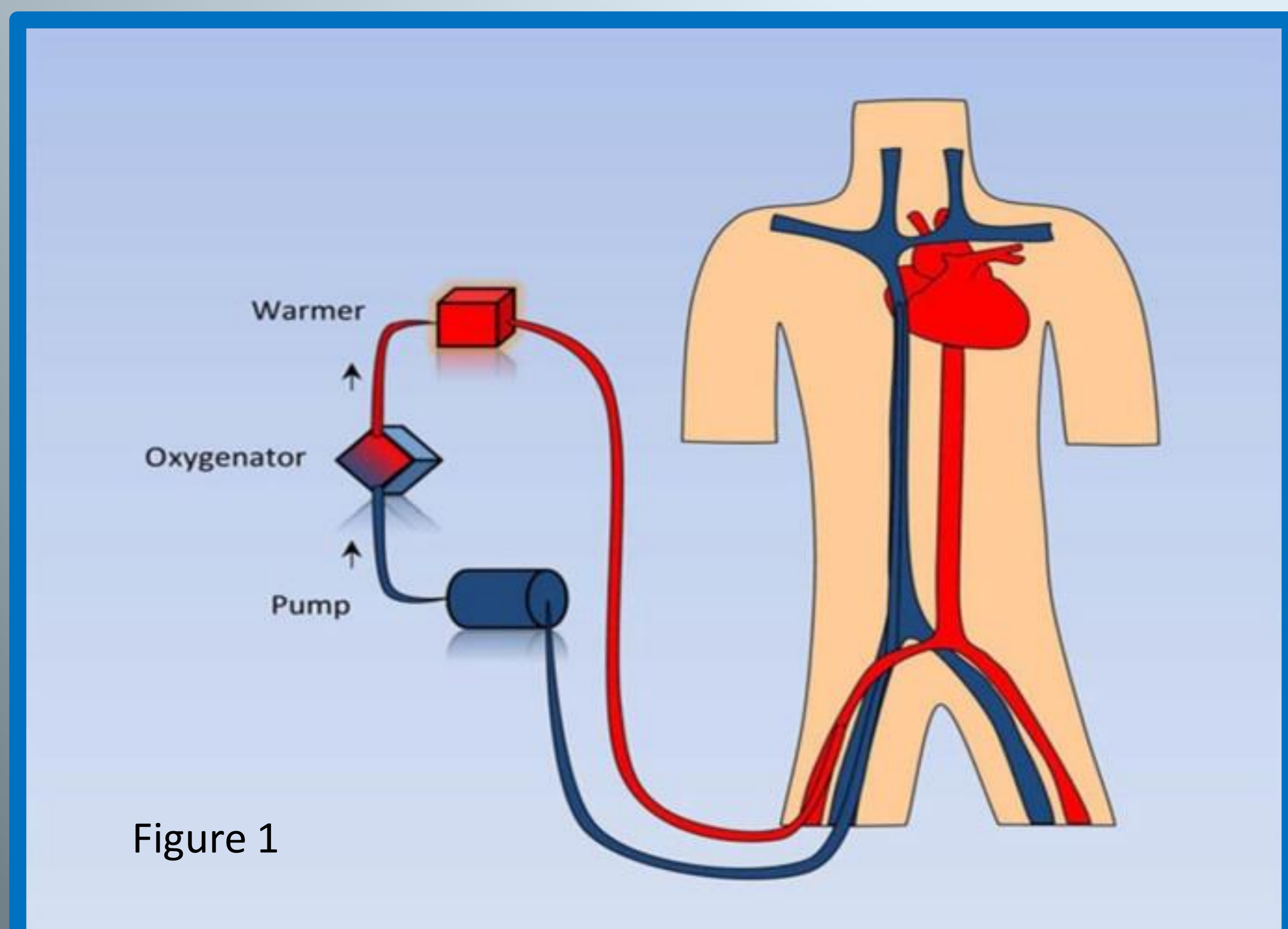


Figure 1