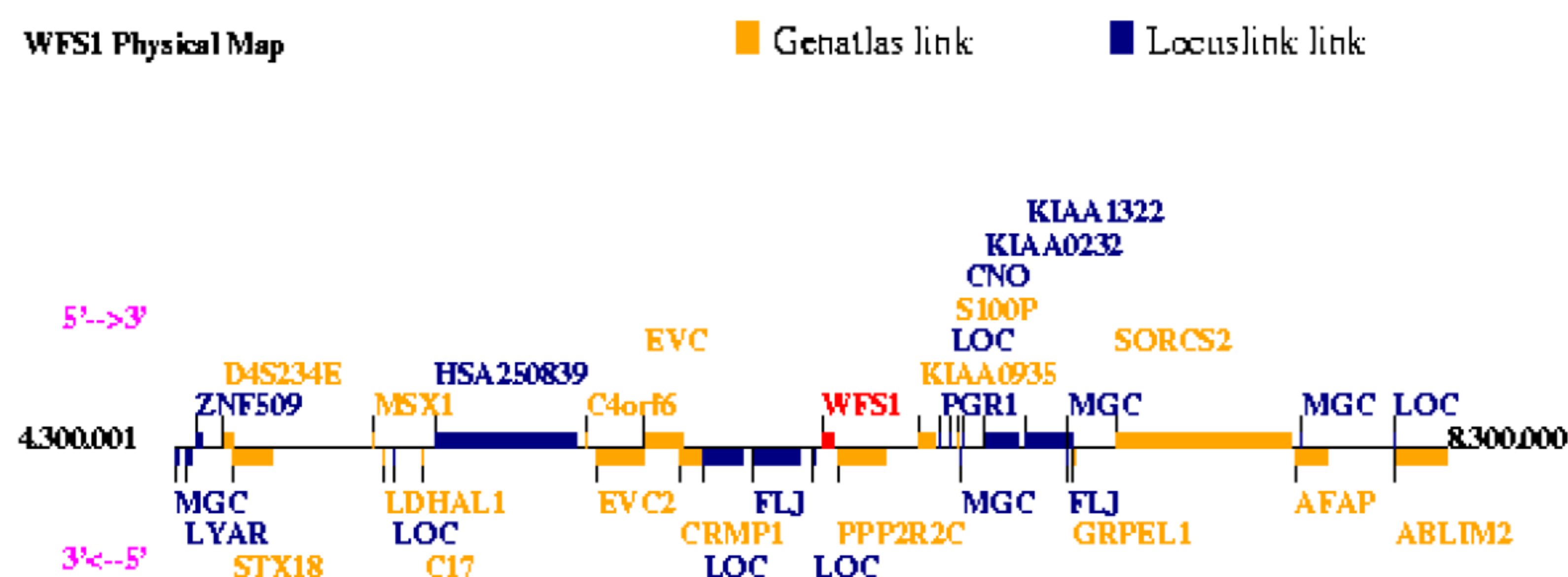


# Pediatric case of atypical course of DIDMOAD (Wolfram) syndrome in Armenia

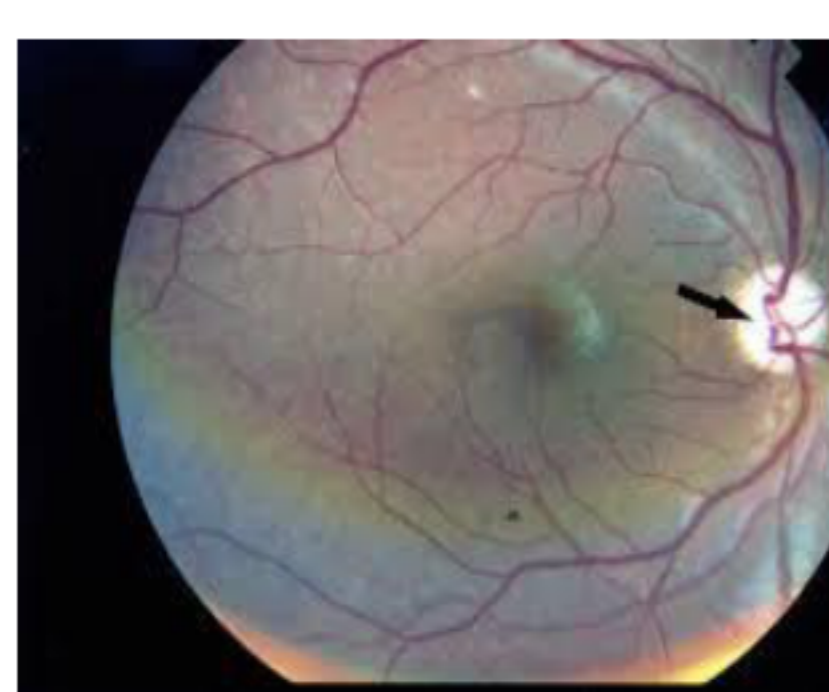
Bayburdyan G.M., Aghajanova Y.M,  
Yerevan State Medical University after M.Heratsi, Yerevan, Armenia

**Introduction:** Wolfram Syndrome is a rare autosomal recessive progressive neurodegenerative disorder with estimated prevalence of 1 in 500,000 r, also known as DIDMOAD syndrome for its four most common features (Diabetes Insipidus, Diabetes Mellitus, Optic Atrophy and Deafness (1,2). In the author's version, first described in 1938, Wolfram syndrome included atrophy of the Optic Atrophy and DM(3). An analysis of its clinical manifestations in 45 patients allowed T.G. Barrett et al. come to the conclusion that this is one disease, and the number of components patients depend on the age and disease duration as not all manifestations occur simultaneously. Patients present with nonautoimmune and non-HLA linked diabetes mellitus associated with optic atrophy in the first decade, diabetes insipidus and sensorineural deafness in the second decade, renal tract abnormalities early in the third decade and multiple neurological abnormalities, like cerebellar ataxia, myoclonus, and psychiatric illness early in the fourth decade.(4)



Findings from different studies suggest that Wolfram is contributed by alterations in genes located on chromosome 4 or alternatively, in the mitochondrial DNA (5). Mutation in the WFS1 gene account for more than 90 percent of Wolfram syndrome type 1 cases. WFS1 produces a protein called wolframin that is thought to regulate the amount of calcium in cells Since the initial recognition of the WFS 1 gene by Inoue et al(6), different research has determined more than 50 distinct mutations of this gene. Accordingly, it is postulated that Wolfram is genetically heterogenic (5).

**Case report:** An 8 years old boy was diagnosed with type 1 diabetes with ketosis on presentation and treated with insulin. However, upon diabetes compensation polydipsia and polyuria continued and the following week diabetes insipidus was diagnosed. MRI of the brain was only significant for posterior arachnoid cyst 1.5x2.5x1.7 cm between the cerebellar hemispheres. Genetic analysis for Wolfram syndrome was not available at that time, therefore patient underwent annual optic nerve funduscopy, audiometry and ultrasound of the urinary tract. After 5 years, he developed hearing loss and early signs of macular atrophy, as well as ureteral dilation. Finally, genetic analysis was abroad and WFS1 gene mutation was identified.



Photographic image of the patient right eye showing optic atrophy without diabetic retinopathy  
Wolfram syndrome.

**Conclusion:** Cases with Wolfram should be followed all their lives. In this case, rehabilitation to a normal social life is possible with good follow-up and treatment. In our country, only two cases of Wolfram syndrome (genetically proven) are reported, and we haven't enough experience of following up such patients. Taking into account that in some countries genetic analysis for Wolfram Syndrome may not be readily available, annual survey for all the components of the syndrome is recommended. This is especially important in atypical and fast progressing cases of Wolfram syndrome.

- 1.Barrett TG, Scott-Brown M, Seller A, Bednarz Amy, Poulton K, Poulton J. The mitochondrial genome in Wolfram syndrome. J Med Genet. 2000;37(6):463–466. doi: 10.1136/jmg.37.6.463. [PMC free article] [PubMed] [Cross Ref]
- 2.Kinsley BT, Swift M, Dumont RH, Swift RG. Morbidity and mortality in the Wolfram syndrome. Diabetes Care. 1995;18(12):1566. doi: 10.2337/diacare.18.12.1566. [PubMed] [Cross Ref]
3. Wolfram DJ, Wagener HP. Diabetes mellitus and simple optic atrophy among siblings: report of four cases. 1938. pp. 715–718.
- 4.Barrett TG, Bunday SE, Macleod AF. Neurodegeneration and diabetes: UK nationwide study of Wolfram (DIDMOAD) syndrome. Lancet. 1995;346(8988):1458–1463. doi: 10.1016/S0140-6736(95)92473-6. [PubMed] [Cross Ref]
- 5.Seyhmus A, Ugur K, Ihsan C, Kaan U, Hasan K. Wolfram Syndrome: Case Report and Review of the Literature. Compr Ther. 2007;33(1):18–20. doi: 10.1007/s12019-007-0007-z. [PubMed][Cross Ref]
- 6.Inoue H, Tanizawa Y, Wasson J, Behn P, Kalidas K, Bernal-Mizrachi E, Mueckler M, Marshall H, Donis-Keller H, Crock P, Rogers D, Mikuni M, Kumashiro H, Higashi K, Sobue G, Oka Y, Permutt MA. A gene encoding a transmembrane protein is mutated in patients with diabetes mellitus and optic atrophy (Wolfram syndrome) Nat Genet. 1998;20:143–148. doi: 10.1038/2441. [PubMed] [Cross Ref]

