

Gynaecomastia Due to hCG Producing Metastatic Germ Cell Testicular Tumour

Dr Muhammad M Alam , Dr A W Safi, D H Bajwa, Dr Neil Gittoes

University Hospital Birmingham UK

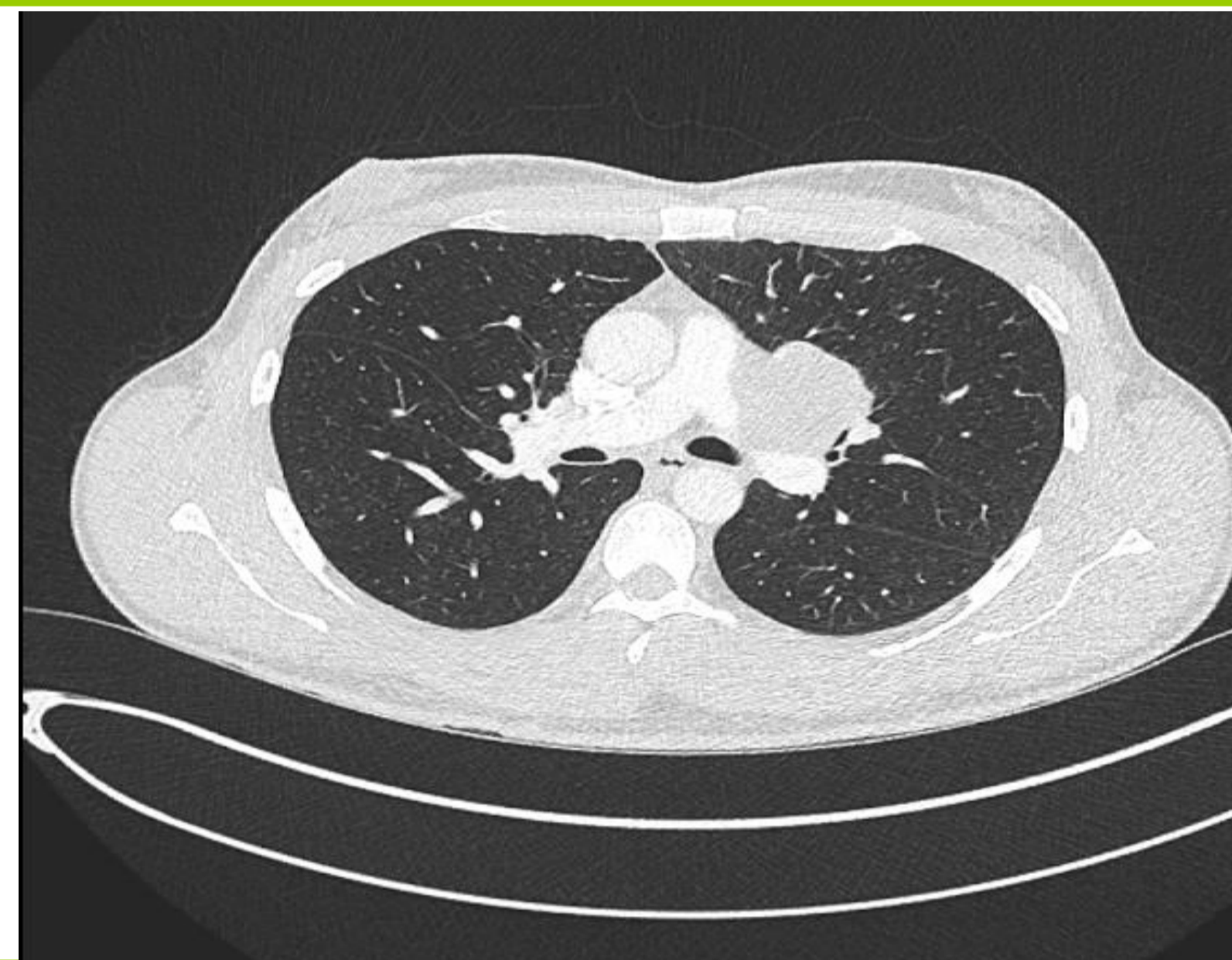
University Hospitals **NHS**
Birmingham
NHS Foundation Trust

Objectives

To describe a 32 years old patient who presented to endocrine clinic with painful gynaecomastia.

Methods

We are presenting clinical and radiological course of rare germ cell testicular tumour leading to gynaecomastia.



CT Chest Showing Left Hilar Lymphadenopathy

Results

A 32 years old patient presented to endocrine clinic with symptoms of painful lumpiness of nipples for last 6 months. There was no history of discharge from nipples and he has not noticed any other lumps in his body. He is not on any regular medications, he did regular exercise and denied any steroid intake. There is no history of any weight loss. There is a history of increase hair growth and acne of chest and back. On examination there is no palpable mass in his testis and he had bilateral gynaecomastia.

His Hormonal profile showed testosterone 39 , oestradiol 687 pmol/L, 17- OH Progesterone 11.5 nmol/L, Beta HCG 4838 IU/L, Alph Fetoprotein 436 KU/L, LH <0.5 IU/L, Progesterone 3.7 nmol/L, Prolactin 369 mu/L.

CXR showed left hilar mass. CT Thorax showed Left Hilar Lymphadenopathy. Ultrasound testis showed heterogenous lesion in left testis. Left Orchidectomy was carried out and histology showed mixed germ cell tumour Seminoma 50%, Embryonal Carcinoma 50%. Patient discussed in urology MDT and started on chemotherapy.

Conclusions

Gynaecomastia is a common disorder , hormonal work up including HCG beta subunit should be done in an adult male patient presenting with rapidly progression or recent onset of painful gynaecomastia. Testicular tumour should be considered in the differential diagnosis of gynaecomastia . Testicular cancers are very sensitive to chemotherapy and curable even when metastatic. Cure rate for good risk disease is 90-95%.

References

1. Braunstein GD. Gynecomastia. N Engl J Med 1993;328: 490-5. [PubMed]
2. Daniels IR, Layer GT. Testicular tumours presenting as gynaecomastia. Eur J Surg Oncol 2003;29: 437-9. [PubMed]