

ADDISON DISEASE IN ANTIPHOSPHOLIPID SYNDROME – CASE REPORT

DIANA OLIVEIRA, MÁRCIA ALVES, DANIELA GUELHO, LUÍS CARDOSO, NUNO VICENTE, DIANA MARTINS, ADRIANA LAGES, MARA VENTURA, SANDRA PAIVA, FRANCISCO CARRILHO

ENDOCRINOLOGY DEPARTMENT | COIMBRA HOSPITAL AND UNIVERSITY CENTER, COIMBRA, PORTUGAL

18th European Congress of Endocrinology, 2016

INTRODUCTION

- ▶ Primary adrenal insufficiency or Addison Disease (AD) is a **potentially fatal condition if not diagnosed in time**.
- ▶ Antiphospholipid syndrome (APS) is characterized by recurrent arterial / venous thrombotic events due to complex interactions between antiphospholipid antibodies, endothelium and platelets.
- ▶ AD is a rare APS complication (< 0,5% of APS cases), although it is **the most common endocrine manifestation of the syndrome**, and it is caused by **adrenal venous thrombosis and consequent hemorrhagic infarction**.

CASE REPORT

- ▶ Caucasian woman, 36 years old
- ▶ APS diagnosis since the age of 24; arterial hypertension
- ▶ Medical history of multiple thrombotic events
 - ▶ deep vein thrombosis
 - ▶ spontaneous abortions (G3 P0)
 - ▶ splenic vein thrombosis; hypersplenism; thrombocytopenia
 - ▶ iatrogenic hemorrhagic events
- ▶ 9 – 22/11/2010: hospitalization for acute renal failure (creatinine 3,63mg/dL) after spontaneous abortion. Discharged under corticosteroid therapy (prednisolone 1mg/Kg/day, progressive dose reduction)

Abdominal CT 10/11/2010: “heterogeneous nodular lesion with high spontaneous density, suggestive of hematoma, in the right adrenal gland (72 x 50mm); left gland poorly visualised; volumous splenomegaly”

- ▶ 26/12/2010 (1 week after suspending prednisolone): admitted to the emergency department:

NAUSEA, PERSISTING VOMITING, ASTHENIA (4 days)

Medicated then with warfarin, pantoprazole, nifedipine and furosemide

Normotensive (patient prone to hypertension)

- ▶ Initial analytical study: **HYPONATREMIA (114 mmol/L)** and **HYPERKALIEMIA (7,9 mmol/L)**, significant worsening of renal function (creatinine 4,90 mg/dL)

- ▶ Readmitted and restarted on therapy with prednisolone. 29/12/2010 (9 a.m.), under prednisolone 40mg id:
 - cortisol 1,3 ug/dL (5-25)
 - ACTH 15 pg/mL (9-52)

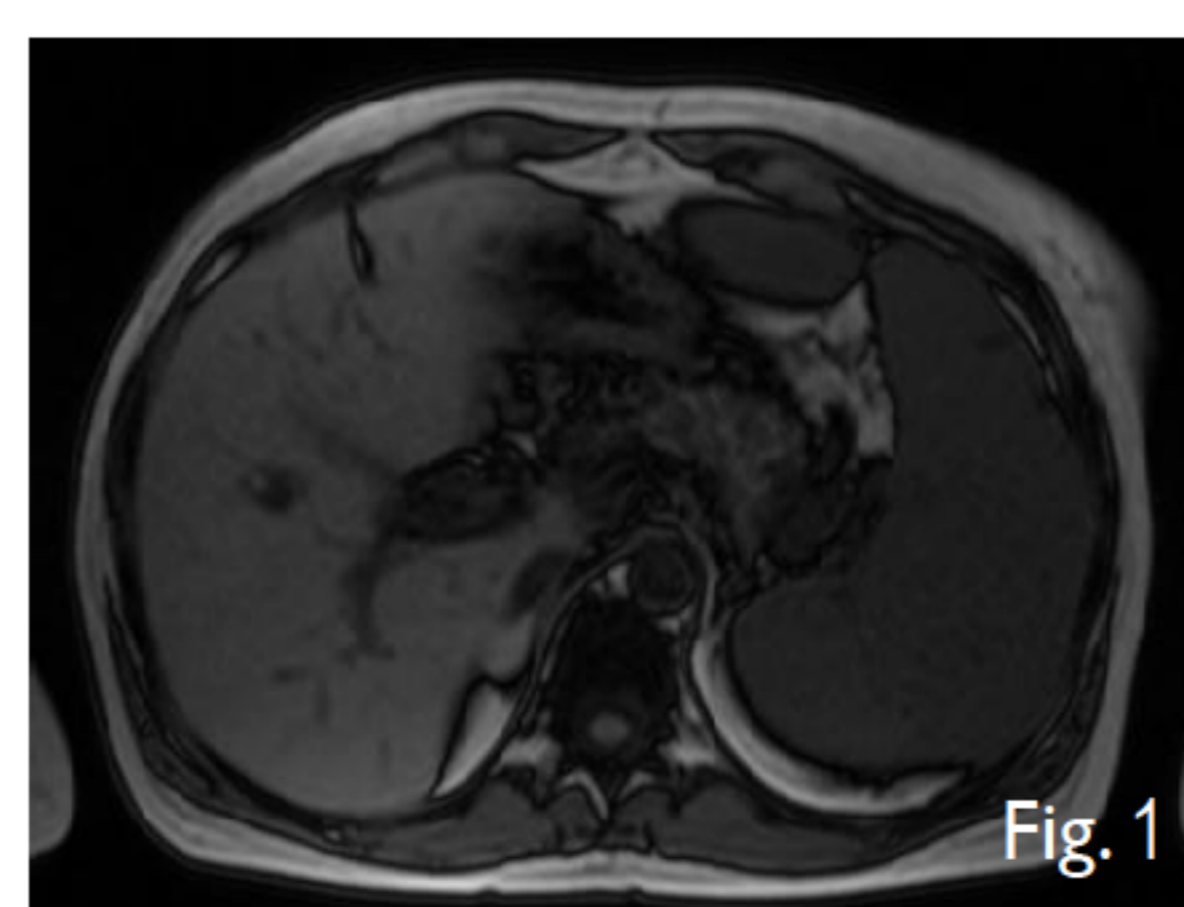
∴ Probable diagnosis: **PRIMARY ADRENAL FAILURE**

She initiated **glucocorticoid and mineralocorticoid replacement** with good clinical and analytical response (discharged with hydrocortisone 10mg +5mg +5mg and fludrocortisone 0,05mg id)

Further study after stabilization (Endocrinology Department) 1/03/2011 (8 a.m.), after suspending hydrocortisone for 48h:

- cortisol <1 ug/dL (5-25)
- ACTH 138 pg/mL (9-52) ∴ **Diagnostic confirmation**

aldosterone < 7,0 pg/mL (40-310)
active renin 4,9 uU/mL (7-76)
DHEA-SO4 < 0,2 ug/mL (0,35-4,3)
androstenedione < 0,3 ng/mL (0,5-3,4)
17-OH-progesterone 1,70 ng/mL (0,2-1,8)
21-hydroxylase antibodies negative
no anterior pituitary deficits
normal thyroid function
creatinine 1,68 mg/dL, normal ionogram



Abdominal MRI 14/05/2015 (Fig. 1): small nodule with T2 hypointensity and T1 hyperintensity – reabsorption of adrenal hematoma

Currently treated with hydrocortisone 15mg + 10mg + 5mg, fludrocortisone 0.05 mg id, warfarin and antihypertensives. Continues to be followed in regular Endocrinology consultation.

CONCLUSION

- ▶ Based on the clinical presentation, analytical study and adrenal imaging, the diagnosis of AD was established in this case.
- ▶ High index of clinical suspicion for AD in APS is needed – in suspected cases, the diagnosis should be investigated and treatment promptly initiated.
- ▶ Conversely, the possibility of APS should be considered in patients with AD of unknown etiology, after exclusion of more common causes.

