

Regional UK Case Series Evaluating Phenotypic and Radiological Signs of Patients with SHOX mutation

Authors: Dr A Childs*, Dr J Ferguson*, Dr C Burren†, Dr E Crowne†, Dr C Moudiotis*

*Royal Devon & Exeter Hospital NHS Trust †Bristol Royal Hospital for Children, University Hospitals Bristol NHS Foundation Trust.

Background

The short stature homeobox (SHOX) gene produces transcription factor proteins which act during early embryonic development to control the formation of the body's skeleton. One copy of the SHOX gene is located on each of the sex chromosomes (Xp22.33 and Yp11.3). Homozygous deletions are associated with Langer mesomelic dysplasia, heterozygous deletions with Leri-Weill dyschondrosteosis. Deletions of the entire SHOX gene or mutations within or near the gene have been identified in children with short stature. This short stature is usually described as idiopathic i.e. it is not associated with the characteristic features of a disease or syndrome, but some children will have subtle skeletal abnormalities.

The estimated prevalence of SHOX mutation in children with idiopathic short stature varies from 2-15%. Rappold et al¹ has published a clinical and auxological scoring system based on a large cohort study to identify these patients. Binder et al² has also demonstrated characteristic radiological signs in standard bone age X-rays.

Aim

To evaluate the phenotypic and radiological signs of a cohort of patients with confirmed SHOX mutation, which may be used to identify patients with short stature for genetic testing.

Method

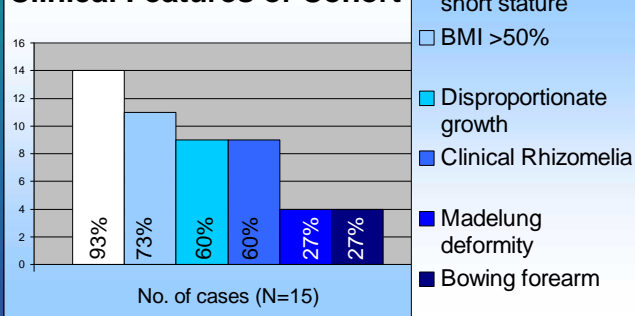
Retrospective note review of cases in the South West of England in 2015. Cases were ascertained by contacting the lead endocrine clinician in 5 units and the regional genetics team.

Results

15 children were identified with the characteristics in the table and graph below:

| Patient Demographic | Mean | Range |
|---------------------|--------|------------------|
| Age (years) | 8.75 | 0.21 to 19.0 |
| Height SDS | - 2.62 | - 4.8 to - 0.77 |
| Weight SDS | - 1.17 | - 4.18 to + 1.58 |
| BMI SDS | + 0.48 | - 1.4 to + 2.58 |

Clinical Features of Cohort



Rappold criteria and measuring disproportion

In addition to BMI > 50%, presence of cubitus valgus, short / bowing forearm, muscle hypertrophy and/or dislocation of the ulna, Rappold suggested two auxological measurements as a screening tool:

- Arm Span : Sitting Height ratio < 96.5%
- Sitting Height : Height ratio > 55.5%

Our cohort

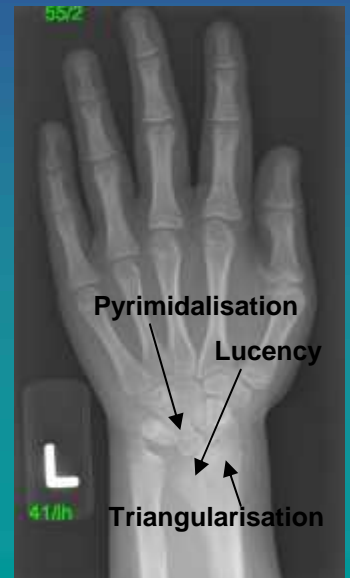
5/15 cases had arm span measured – all of them had a ratio < 96.5%.
7/15 cases had a documented sitting height – 86% had ratio > 55.5%

Bone Age X-ray Analysis

Binder suggested 3 x-rays changes were typical in SHOX mutation, characterised by pyramidalisation, triangularisation and lucency of the ulnar border of the distal radial epiphysis (see diagram).

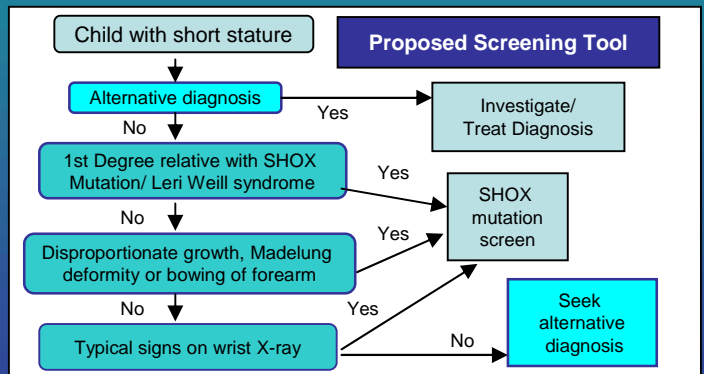
11 patients had a bone age completed and all were analyzed by JF.

- 8 showed one or more of the characteristic changes
- 1 was equivocal
- 2 were too young for analysis



Conclusion and Key Points

- We identified key features that would prompt SHOX mutation analysis in a child with short stature.
- Most endocrinologists would be alerted to the possibility of a SHOX mutation with either a positive family history and/or clinical disproportion. We advocate adding in bone age X-ray analysis in all cases – see flowchart below.
- Alone Rappold criteria are useful but there are limitations e.g. the low positive predictive value (11%) when using the lower cut-off score and the low sensitivity (61%) using the higher cut-off score³.
- Few centers measure arm span or document sitting height. In the first instance we recommend all units to have a sitting height stadiometer available in the assessment of short stature.
- Identifying key clinical, auxological and radiological signs of SHOX mutation could lead to a larger prospective study.



References

1. Rappold G, Blum WF, Shavrikova EP, Crowne BJ, Roeth R, Quigley CA, Ross JL, Neisler B: Genotypes and phenotypes in children with short stature: clinical indicators of SHOX haploinsufficiency. J Med Genet 2007;44:306-313
2. Binder G. Short Stature due to SHOX Deficiency: Genotype, Phenotype and Therapy. Horm Res Paediatr 2011;75:81-89
3. Jorge A, Arnhold I. Anthropometric evaluation of children with SHOX mutations can be used as indication for genetic studies in children of short stature. J Med Genet. 2007; 44 (10) e90