

Metastatic differentiated thyroid cancer with undetectable serum thyroglobulin: diagnostic, management and follow-up challenges

Pedro Marques¹, Teresa C. Ferreira², Lucília Salgado², Rafael Cabrera³, Valeriano Leite¹

E-mail: pedro.miguel.sousa.marques@gmail.com

¹Endocrinology Department, Portuguese Institute of Oncology, Lisbon

²Nuclear Medicine Department, Portuguese Institute of Oncology, Lisbon

³Pathology Department, Portuguese Institute of Oncology, Lisbon

Introduction

- Serum thyroglobulin (Tg) is a reliable marker in patients with differentiated thyroid carcinoma (DTC). Distant metastases of DTC usually presents with higher levels of Tg, which are useful to follow the disease evolution¹.

- Tg levels depend on tumor type, volume and proportion of cells synthesizing Tg within the tumor. Molecular heterogeneity of Tg due to diverse mRNA alternative splicing, heterogeneity in glycosylation and iodination, and the use of different Tg assays may also explain variable concentrations of Tg².

Case report

- A 52-year-old woman underwent a subtotal thyroidectomy in 1993 because of a growing nodule. The histology was follicular thyroid carcinoma.

- Eight years later, multiple lung nodules were identified in a thorax-CT scan. A biopsy of one of the pulmonary lesions was compatible with metastatic thyroid carcinoma (**Figure 1**). She was referred to our hospital.

- The thyroidectomy was completed and seven radioiodine treatments were administered (total activity of 800 mCi). The tail-end-scan following each treatment showed uptake in the lung metastases (**Figure 2**), except of the last scan where lung uptake was lost. Stimulated-Tg throughout these radioiodine treatments was consistently undetectable (<0.2 ng/mL) with TSH between 40-93 mIU/mL.

- During the 13-years follow-up, suppressed-Tg has been consistently undetectable and the measurement of TgAb negative, despite the progression in size and number of metastatic lesions (**Figure 3**). The non-radioiodine avid lung metastasis were proven to be fluorodeoxyglucose (FDG)-avid (**Figure 2**).

- Currently, the patient is asymptomatic with a progressive metastatic DTC, without biochemical evidence of the disease - undetectable Tg and TgAb (tested by 3 different laboratorial assays).

Discussion

- Serum Tg is an excellent tumor marker for DTC, and serial monitoring is valuable for the follow-up of this condition. DTC with systemic dissemination usually has measurable Tg.

- Undetectable serum Tg in recurrent/metastatic DTC may not necessarily predict neither radioiodine uptake nor adverse prognosis, but it imposes important diagnostic, management and follow-up challenges. In such uncommon cases, imaging methods (CT, MRI and PET) should supplement Tg and TgAb measurements in order to allow a correct follow-up and management strategy.

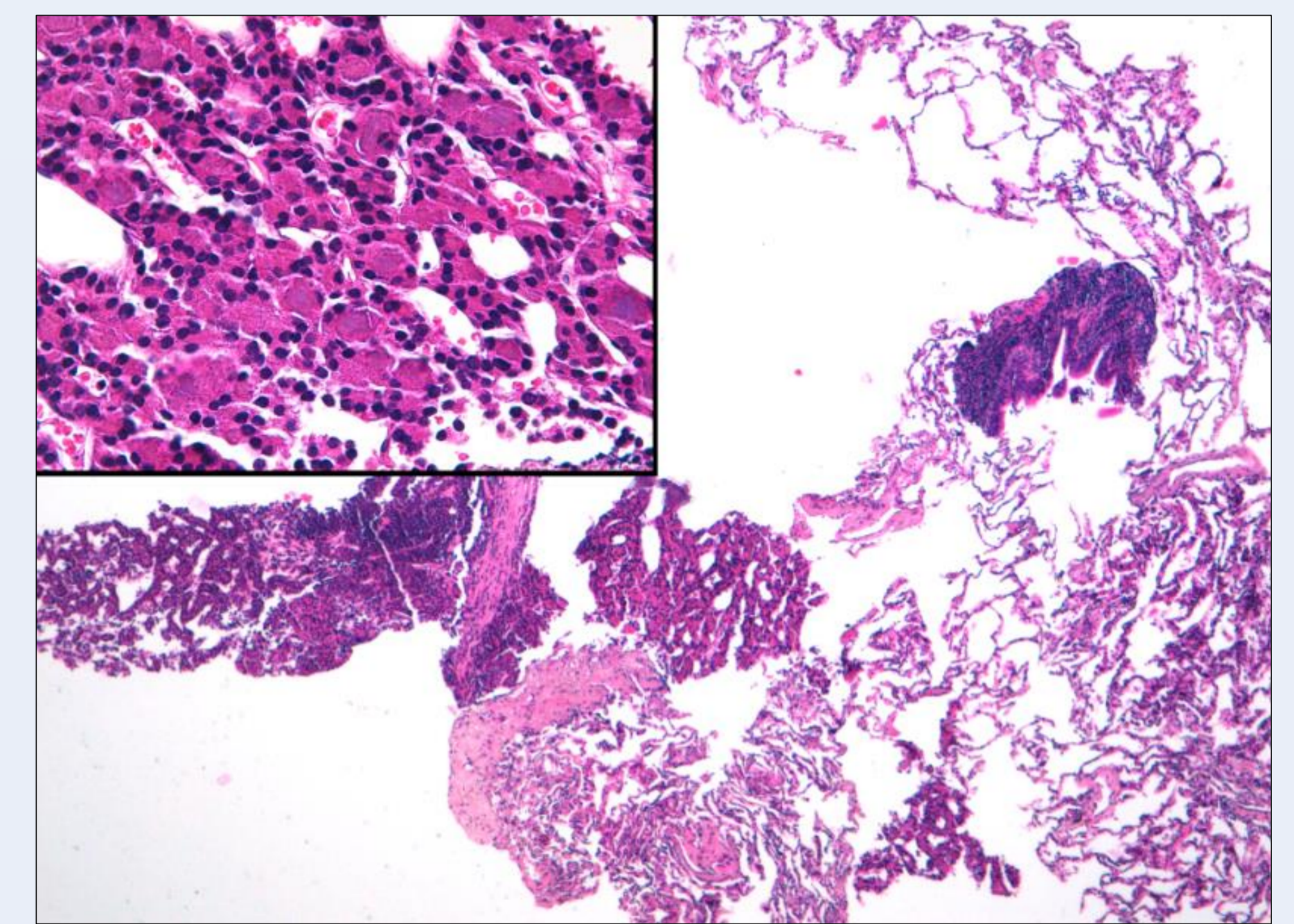


Figure 1: Histological analysis of the lung showing metastatic well-differentiated thyroid carcinoma (hematoxylin-eosin stain).

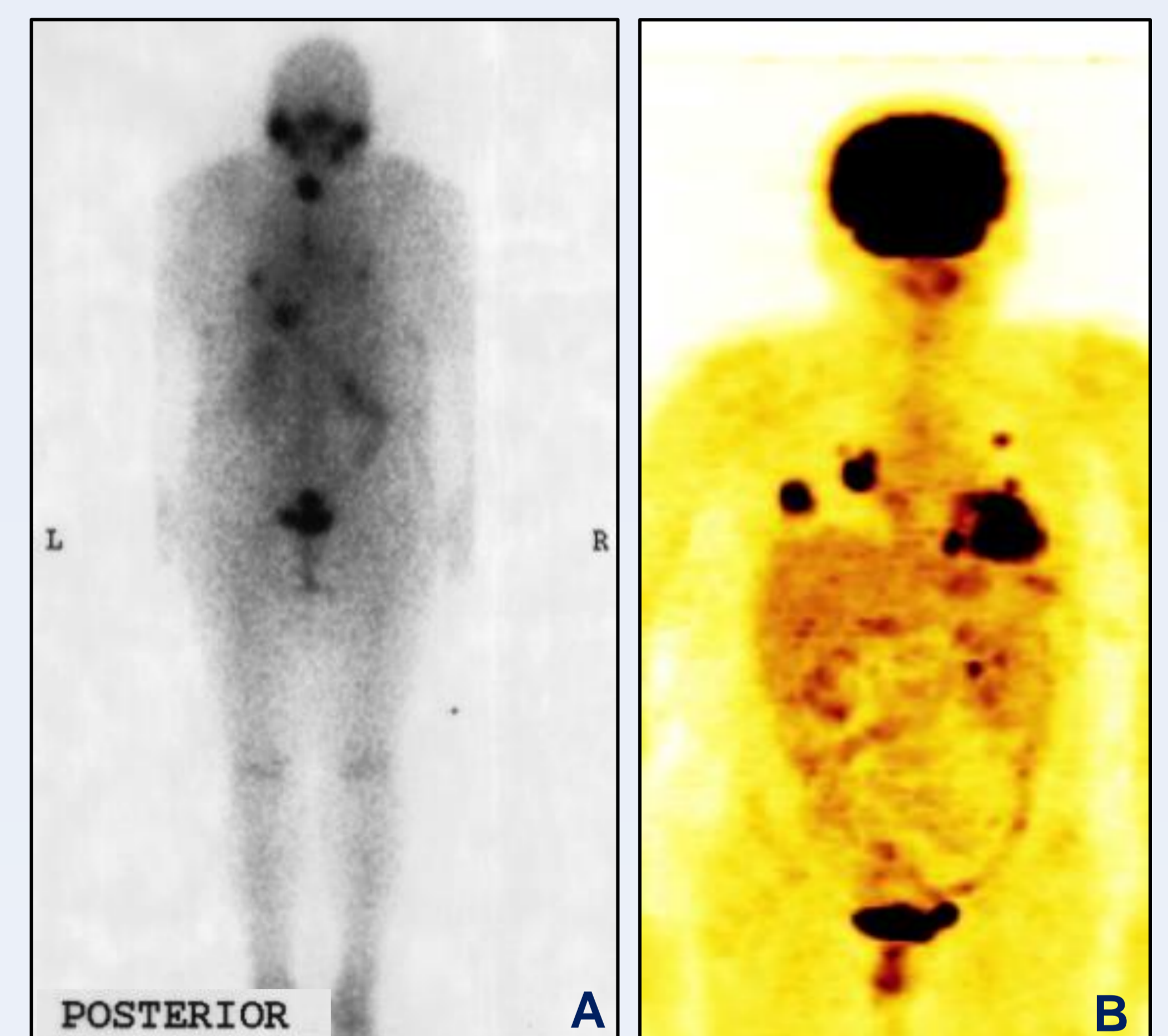


Figure 2: Post-radioiodine whole-body scan showing iodine-avid lung lesions (A); FDG-PET scan showing uptake in the lung metastasis (B).

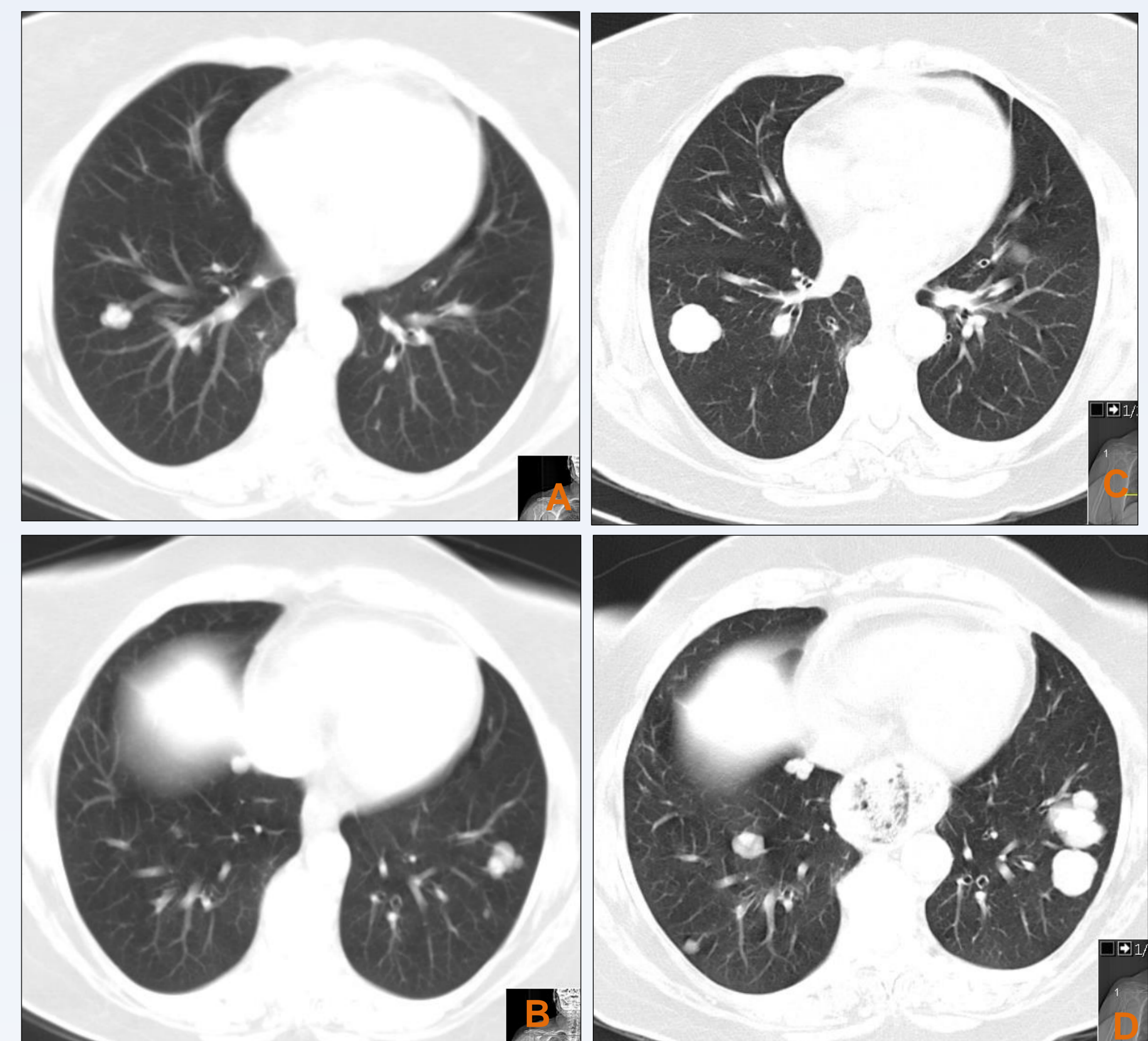


Figure 3: CT evaluation of the lung secondary lesions, at diagnosis (A,B) and 13-years after (C,D).

1. Westburey C, Vini L, Fisher C, Harmer C. Recurrent differentiated thyroid cancer without elevation of serum thyroglobulin. *Thyroid* 2000;10(2):171-176
2. Giovannella L, Clark P, Chiovato L, Duntas L, Elisei R, et al. Thyroglobulin measurement using highly sensitive assays in patients with differentiated thyroid cancer: a clinical position paper. *Eur J Endocrinol* 2014;171:R33-R46