

Dr E Austin, Dr B Miller, Dr A Rahim, Sister L. Shepherd, Dr A Bates
Department of Diabetes and Endocrinology, Heart of England Foundation Trust

BACKGROUND

Adrenal incidentalomas are a common clinical dilemma and are seen on 4% of abdominal CT scans (1), with incidence rising with increased utility of cross-sectional imaging (2, 3).

Investigation of these lesions aims to exclude malignancy and hormonally active lesions. The current standard for management is the AACE guidelines as summarised in figure 1.

Zeiger et al states that of all adrenal incidentalomas detected, 80% are non-functional adenomas, 6% functional adenomas, 5% phaeochromocytomas, <5% adrenocortical carcinomas and 2.5% metastases (2).

A literature review by Cawood et al suggested that the conversion rates of benign adenomas to functional or malignant lesions was <1% and <0.2% respectively (4).

OBJECTIVES

This study was performed to:

1. Review the incidence of malignant or hormonally active lesions detected as adrenal incidentalomas within this single centre, compared to the literature review.
2. Evaluate whether the current recommendations for investigating adrenal incidentalomas are appropriate given the low risk of progression to functional or malignant lesions.

RESULTS

Table 1 summarises the diagnoses and outcome in 145 adrenal incidentalomas. In figure 2, the incidence of each diagnosis in this study is compared to the literature review.

Radiology results:

- 65 (45%) of the initial scans were diagnostic of a benign adenoma (CT density <10HU)
 - Of these, 27 had additional diagnostic imaging – MRI or CT, all of which confirmed the original diagnosis.
- 43 (30%) were indeterminate on the original scan, but were deemed to be benign adenomas following further imaging (In and out of phase MRI, CT density <10HU, CT contrast washout >60% at 10 minutes).
- 7 (5%) had indeterminate detection scans with no repeat imaging (comorbidity or failure to attend).
- All malignant lesions, metastases and phaeochromocytomas had abnormal initial imaging.
- The single case of Conn's syndrome, had an indeterminate initial and repeat scan.

Biochemical results:

- 135 (93%) of the cohort was hormonally inactive.
- All 5 phaeochromocytomas had raised urinary metanephrines.
- 7 (5%) had a 9am cortisol >100 following 1mg dexamethasone, none of whom had symptoms/signs consistent with cortisol excess.
 - all were deemed to be normal after further investigation
- 3 (2%) had abnormal renin: aldosterone levels (>72).
 - 1 diagnosed as Conn's adenoma (also hypertensive and hypokalaemic)
 - 2 on-going investigation/monitoring
- 2 males had elevated DHEAS levels, both of whom had abnormal imaging.
 - 1 was found to have a phaeochromocytoma

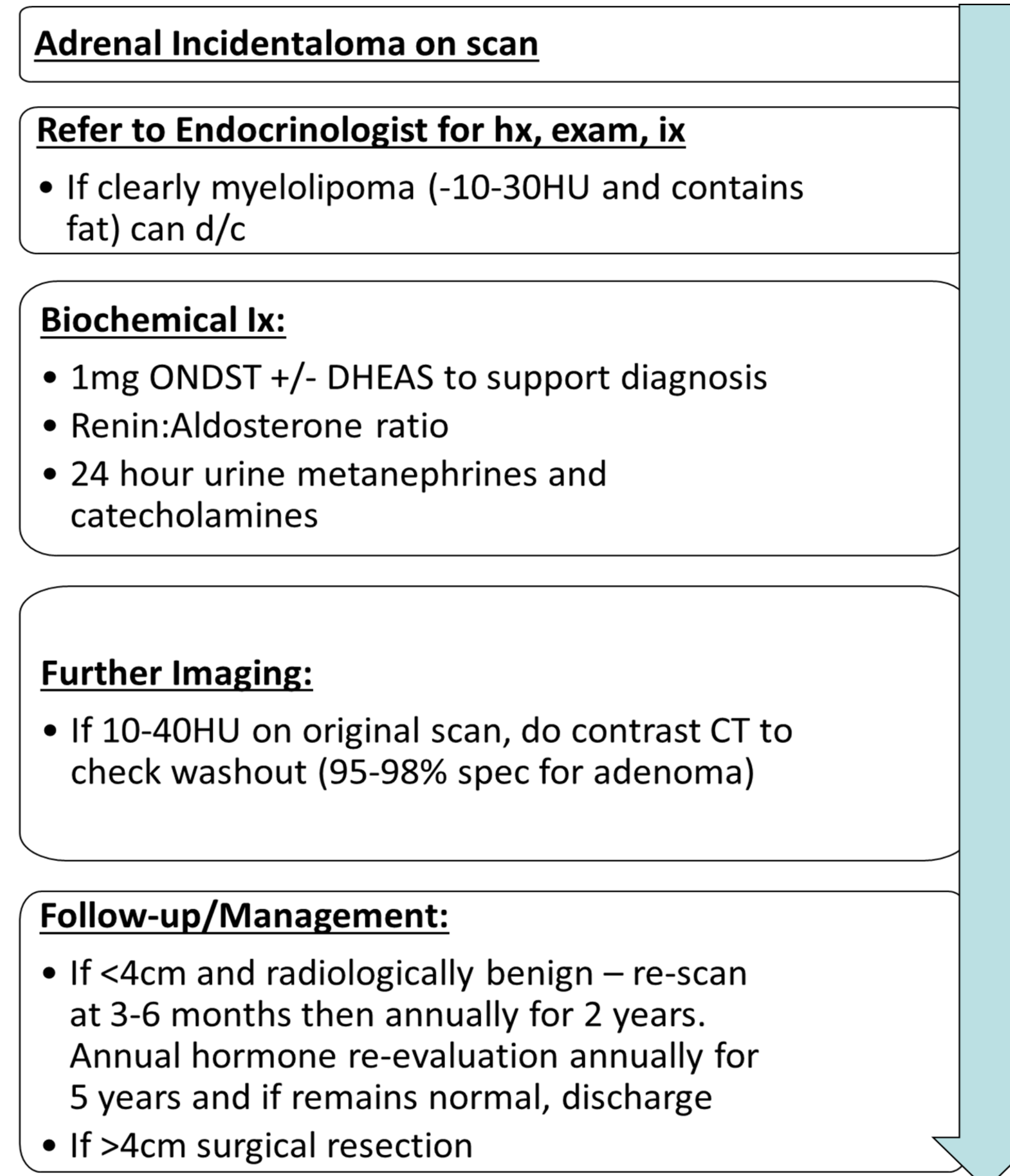
CONCLUSION

None of those tumours considered to be benign adenomas on imaging proved to be hormonally active and endocrine screening may therefore not be necessary.

All hormonally active and malignant lesions had abnormal or indeterminate imaging.

This study suggests that in patients who have a) no symptoms or signs, b) are normotensive, c) are normokalaemic and d) have imaging features consistent with a benign adrenal adenoma, further investigation is unrewarding.

Figure 1 – AACE Guidelines (2) for investigation and management of adrenal incidentalomas



METHODS

A retrospective review was performed of 145 consecutive cases of Adrenal Incidentalomas referred to Endocrinology from January 2013 - January 2015.

Data Collected:

- Age
- Laterality
- Imaging results
- Biochemistry result
- BP
- Diagnosis
- Outcome

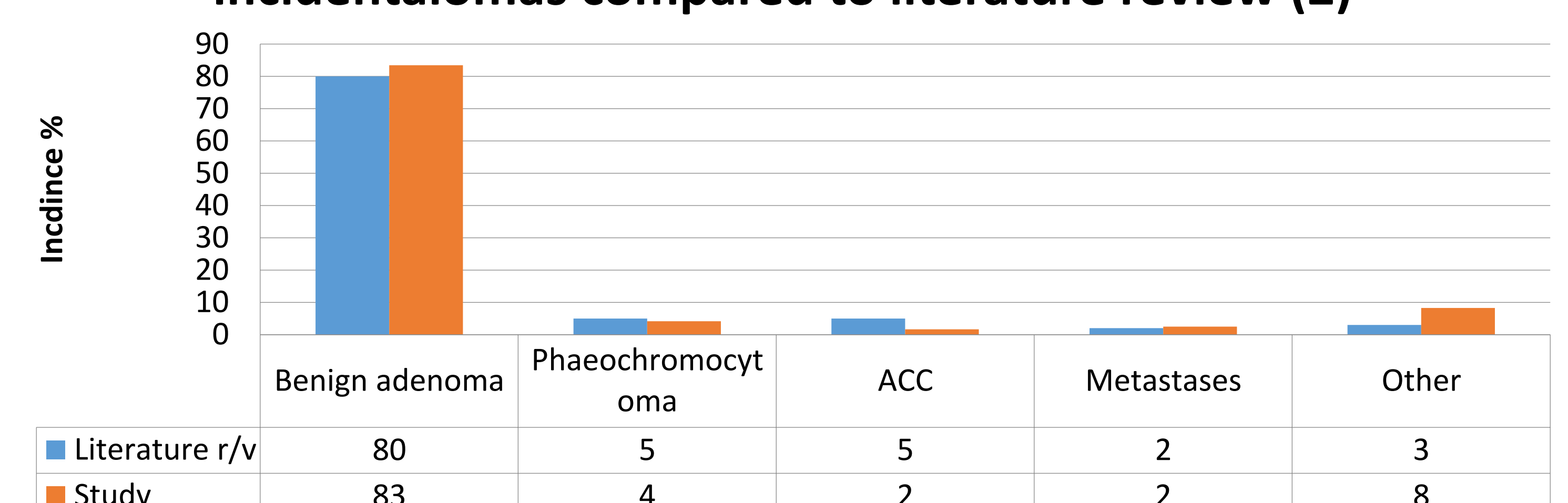
Cohort Demographics:

- Mean age 65 years (21-95)
- M:F = 51:94
- Laterality: 46 right, 88 left, 10 bilateral, 1 unknown (imaging at different hospital)

Table 1 – Summary of diagnoses made following detection of Adrenal Incidentaloma

Diagnosis	Incidence	Outcome
Non-functional benign adrenal adenoma	119	95 discharged 8 awaiting further investigation 8 DNA 5 Surgically excised 3 not investigated due to comorbidity
Indeterminate adrenal mass	11	5 not investigated due to comorbidity 3 metastatic lesions 2 ACC 1 resected – benign adenoma
Phaeochromocytoma	5	5 resected
Angio/myolipoma	4	1 resected 3 discharged
Adrenal cyst	2	1 resected 1 discharge
Functional adrenal adenoma	1	1 Conn's
Other	3	1 ganglioneuroma 1 sarcoma 1 gastric diverticulum

Figure 2 - Incidence of Diagnoses from adrenal incidentalomas compared to literature review (2)



REFERENCES

1. Kloos RT et al. Incidentally discovered adrenal masses. Endoc Rev 1995;16:460-484.
2. Zeiger M.A et al. American Association of Clinical Endocrinologists and American Association of Endocrine Surgeons Medical Guidelines for the Management of Adrenal Incidentalomas AACE Guidelines 2009.
3. Bovio S et al. Prevalence of adrenal Incidentaloma in a contemporary computerized tomography series. J Endocrinol Invest. 2006; 29:298-302
4. Cawood et al. Recommended evaluation of adrenal incidentalomas is costly, has high false-positive rates and confers a risk of fatal cancer that is similar to the risk of the adrenal lesion becoming malignant; time for a rethink? European J Endocrinology. 2009; 161: 513-527