

Complete remission of hepatic metastasis after total gastrectomy for a gastric carcinoid tumor type 1: a case report

Tresoldi A.S.^{1,2}, Bonifacio C.³, Pepe G.⁴, Lania A.G.¹, Carnaghi C.⁵

¹Department of Endocrinology, Humanitas Clinical and Research Center, Rozzano (Milan), Italy

²Department of Clinical Sciences and Community Health, University of Milan, Milan, Italy

³Department of Radiology, Humanitas Clinical and Research Center, Rozzano (Milan), Italy

⁴Department of Nuclear Medicine, Humanitas Clinical and Research Center, Rozzano (Milan), Italy

⁵Department of Oncology, Humanitas Clinical and Research Center, Rozzano (Milan), Italy

INTRODUCTION

Gastric carcinoids secondary to autoimmune atrophic gastritis (type 1) are usually well differentiated neoplasms, with an indolent course and an excellent overall prognosis. However, a subset of these tumors (< 5%) may develop advanced disease, with lymph node and/or hepatic metastasis. The pathogenesis of these carcinoids is related to chronic trophic stimuli to enterochromaffin-like (ECL) cells due to chronic hypergastrinemia [1].

Treatments directed to remove the source of hypergastrinemia (such as antrectomy and SSAs) have been used with good results in localized tumors. However, the rare cases described in literature report a persistence of metastatic disease despite these approaches, underlining a probable dedifferentiation of metastases [2].

CLINICAL CASE

A 58-year-old woman was diagnosed with type 1 gastric carcinoid with liver metastasis, documented by abdominal CT and 68GalliumDOTA-peptide PET-CT. Blood exams showed high levels of CgA (596 ng/ml) and gastrin (2283 pg/ml).

The patient underwent total gastrectomy with roux-en-Y anastomosis and local linfoadenectomy; during surgery an hepatic US was performed, showing 7 subcentimeter metastases. Histological examination revealed a neuroendocrine tumor G2 (WHO 2010) of 30 mm, Ki67 20%, 15 mitoses/10 HPF, positive staining for chromogranin and synaptophysine; chronic gastritis and micronodular hyperplasia of endocrine cells was associated.

During the early months of follow up a gradual reduction in size of liver metastases was observed, until the complete disappearance of them.

RESULTS

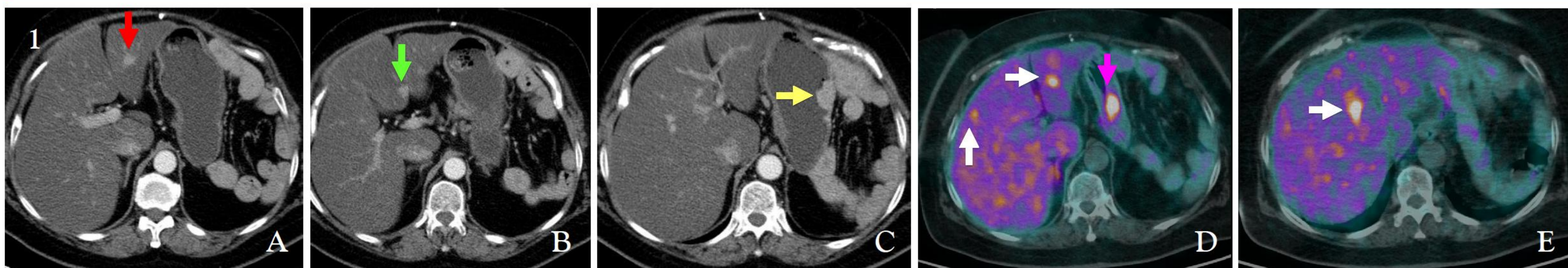


Fig. 1 - Before surgery

A-C) CT scan shows hypervascular hepatic lesions in arterial phase in S3 (red arrow) and S4b (green arrow) and a gastric wall lesion of 3 cm at the greater curvature (yellow arrow)

D-E) 68-GalliumDOTA-peptide PET-CT shows areas of increased tracer uptake at the greater curvature of the stomach (pink arrow) and three foci of increased uptake in the liver, compatible with metastasis (white arrows)

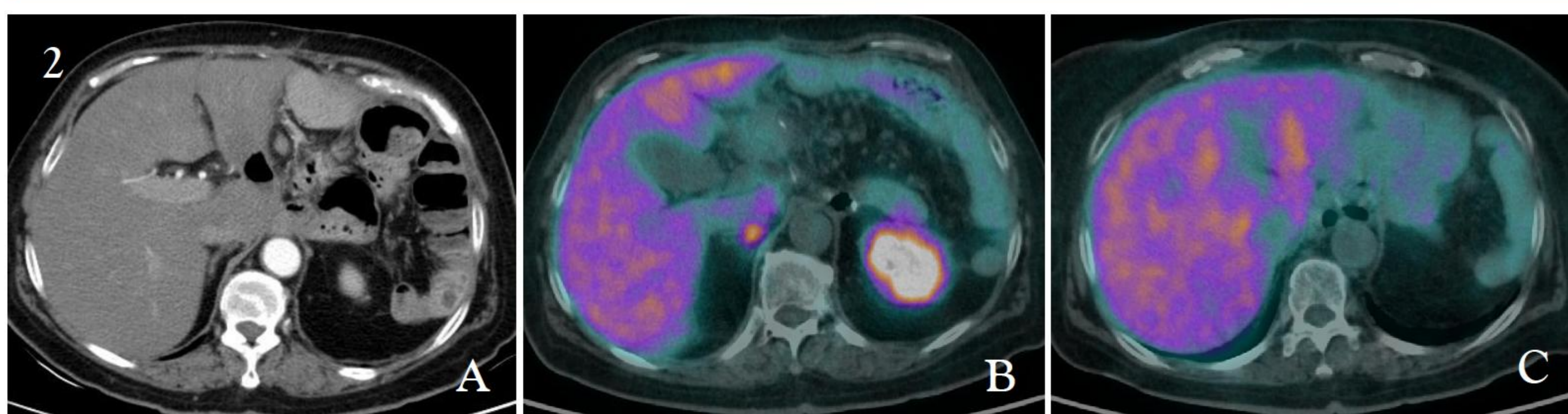


Fig. 2 - 6 months after surgery

A-B) The CT scan performed in arterial phase shows total resolution of hepatic lesions

C) 68-GalliumDOTA-peptide PET-CT doesn't show areas of increased tracer uptake previously detected

CONCLUSIONS

This is to our knowledge the first case ever described in literature of complete remission of liver metastatic type 1 gastric carcinoid after removal of the source of excessive gastrin, showing a possible preservation of responsiveness of metastases to gastrinemic stimuli. This could lead to a possible change in therapeutic approach in these neoplasm.

REFERENCES

1. Grozinsky-Glasberg S., Thomas D., Strosberg J.R., et al. Metastatic type 1 gastric carcinoid: A real threat or just a myth? *World J Gastroenterol* 2013;19:8687-8695.
2. Grozinsky-Glasberg S, Kaltsas G, Gur C, et al. Long-acting somatostatin analogues are an effective treatment for type 1 gastric carcinoid tumours. *Eur J Endocrinol* 2008; 159: 475-482.

