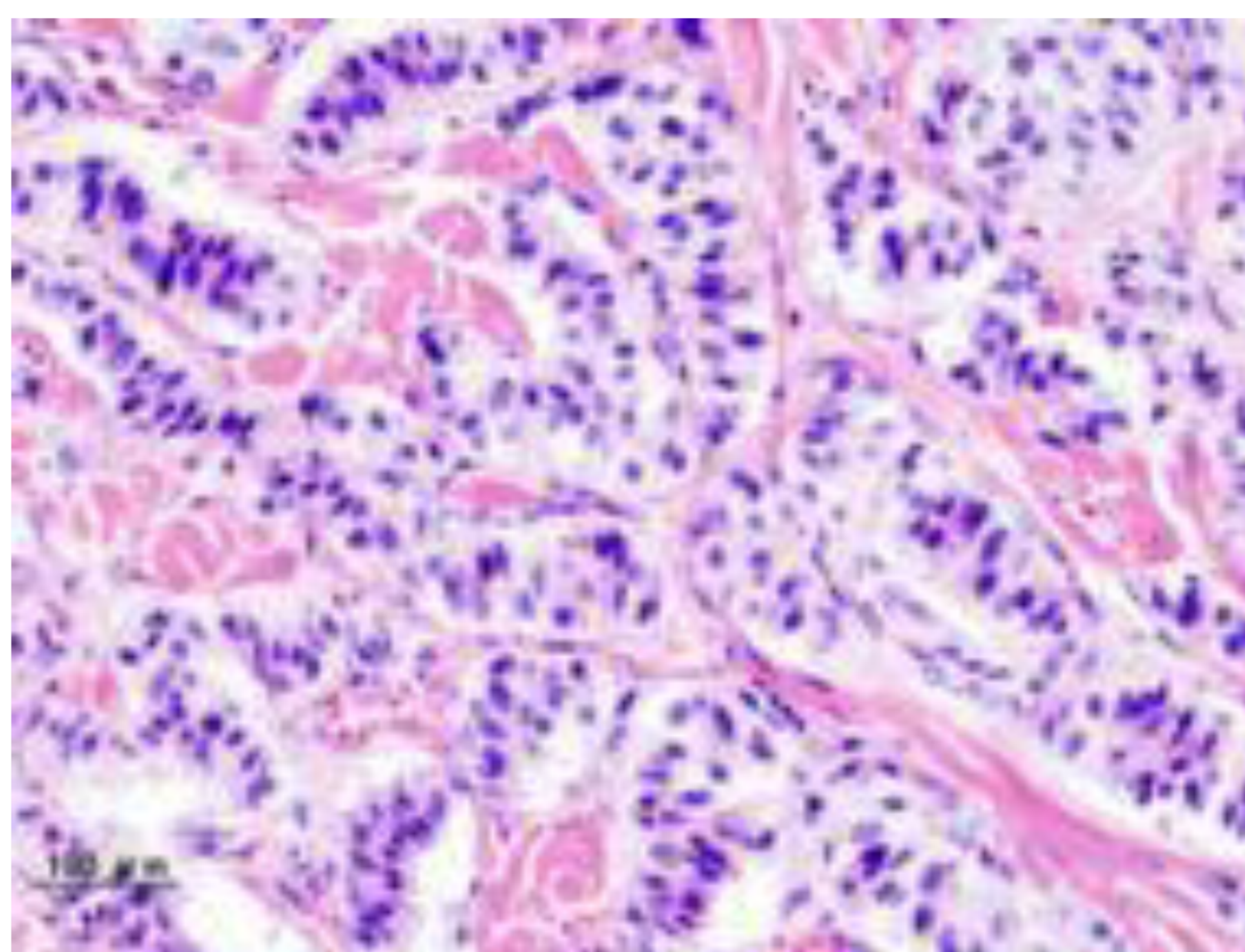


Case report of successfully treated congenital hyperinsulinism in Armenia

Bayburdyan G.M., Arakelyan L.M., Hakobyan S.V., Issa V.S., Markosyan R.L., Navasardyan L.V., Aghajanova Y.M., Yerevan State Medical University after M.Heratsi

Introduction: Congenital hyperinsulinism (CHI) is the most common cause for recurrent hypoglycemia in neonates and infants(1,2,3,4). There are two main types of CHI. The first type is transient CHI, which usually develops soon after birth and resolves spontaneously within the first 3-4 weeks of life and the second type is persistent CHI, developing usually in the later life as well as in the neonatal period, which duration is longer. The differentiation between transient and persistent CHI is not possible on the basis of laboratory test results(8). Transient CHI is believed to be caused mainly by nongenetic factors, e.g., small size for the infant's gestational age or stressful perinatal conditions such as cardiopulmonary disorders. In contrast, persistent CHI has genetic etiologies. However, even with the most comprehensive analysis, the responsible genes can be identified in only 53% of diazoxide-responsive CHI patients (9)although in the case of unresponsive patient, K_{ATP} channel mutations could be identified in most (87.6%-88%) cases (9,10). Uncontrolled hypoglycemia leads to seizures and long-term cerebral damage. The incidence of persistent CHI is generally estimated as 1 in 50,000 live births (5) . Herein, we report a case of congenital hyperinsulinism (persistent hyperinsulinemic hypoglycemia of infancy, nesidioblastosis) and review of the relevant literature regarding on the etiology, pathogenesis, clinical and pathological features, diagnosis and treatment of this disorder. Such a treatment is made possible only by a multidisciplinary team composed of pediatric endocrinologists, surgeons and pathologists who are well experienced in the treatment of CHI (6,7).

Case report: The male infant had been born at 39 weeks' gestation to a 25-year-old mother after an uneventful pregnancy. The birth weight was 2900 g. The Apgar score was 4 at one minute and 7 at five minutes. There was no maternal history of gestational or insulin-dependent diabetes mellitus. The infant was delivered vaginally without complications, presented with tonic-clonic seizures and hypoglycemia of 0.5 mmol/L (normal range 1.7-2.8mmol/L) on the second day of life. Intravenous infusion of 12.5% glucose solutions at a rate of 10-17 mg/kg and dexamethazone 0.8 mg/kg were given to maintain a stable blood sugar level. The plasma insulin level was 32.3 μ U/ml (normal values 2.6-24.9 μ U/ml) and blood sugar level was between 0.5 and 7.2mmol/L on day 30 of his life. Deficiency of counterinsular hormones (cortisol, thyroxin, IGF-1) was excluded. These results suggest nesidioblastosis, or persistent hyperinsulinemic hypoglycemia of infancy (PHHI). Taking into consideration that diazoxide as well as genetic examinations are unavailable in Armenia and patient cannot be weaned off treatment with intravenous glucose infusions it was decided to performe diagnostic laporotomy, which was performed at the age of 30 days (not enough experience of surgeons made impossible intervention earlier). During the operation visual hyperplasia of islands of Langerhans was detected in the area of tail and body of pancreas. Cut tissue was sent to cito-histologic examination and the cito-answer of <<insulinoma>> was received on the basis of that was performed the resection of body and tail (50%) of pancreas with splenectomy (the tail of pancreas and spleen were spliced). According to further pathologic-hystologic examination congenital hyperplasia and displasia of island cells of pancreas: adenomatous nodule- was diagnosed.



CONCLUSIONS and FOLLOW UP: Congenital hyperplasia and dysplasia of pancreatic islet cells and a focal adenomatous hyperplasia was diagnosed by pathological analysis of surgical material, as well as clinical presentation. At present time, the patient is three years old, maintains euglycemia with fractionated feeding and has a normal psychomotor development. This is the first case of diagnosis and successful treatment of congenital hyperinsulinism in Armenia.

1. Avatapalle HB, Banerjee I, Shah S, Pryce M, Nicholson J, Rigby L, et al. Abnormal neurodevelopmental outcomes are common in children with transient congenital hyperinsulinism. *Front Endocrinol (Lausanne)* 2013;4:60
2. Menni F, de Lonlay P, Sevin C, Touati G, Peigne C, Barbier V, et al. Neurologic outcomes of 90 neonates and infants with persistent hyperinsulinemic hypoglycemia. *Pediatrics*. 2001;107:476-479.
3. Steinkrauss L, Lipman TH, Hendell CD, Gerdes M, Thornton PS, Stanley CA. Effects of hypoglycemia on developmental outcome in children with congenital hyperinsulinism. *J Pediatr Nurs*. 2005;20:109-118.
4. Ludwig A, Ziegenhorn K, Empting S, Meissner T, Marquard J, Holl R, et al. Glucose metabolism and neurological outcome in congenital hyperinsulinism. *Semin Pediatr Surg*. 2011;20:45-49.
5. Arnoux JB, Verkarre V, Saint-Martin C, Montravers F, Brassier A, Valayannopoulos V, et al. Congenital hyperinsulinism: current trends in diagnosis and therapy. *Orphanet J Rare Dis*. 2011;6:63.
6. Adzick NS, Thornton PS, Stanley CA, Kaye RD, Ruchelli E. A multidisciplinary approach to the focal form of congenital hyperinsulinism leads to successful treatment by partial pancreatectomy. *J Pediatr Surg*. 2004;39:270-275.
7. Palladino AA, Stanley CA. A specialized team approach to diagnosis and medical versus surgical treatment of infants with congenital hyperinsulinism. *Semin Pediatr Surg*. 2011;20:32-37.
8. Tohru Yorifuji, MD, PhD. Congenital hyperinsulinism: current status and future perspectives *Ann Pediatr Endocrinol Metab*. 2014 Jun; 19(2): 57-68.
9. Snider KE, Becker S, Boyajian L, Shyng SL, MacMullen C, Hughes N, et al. Genotype and phenotype correlations in 417 children with congenital hyperinsulinism. *J Clin Endocrinol Metab*. 2013;98:E355-E363.
10. Kapoor RR, Flanagan SE, Arya VB, Shield JP, Ellard S, Hussain K. Clinical and molecular characterisation of 300 patients with congenital hyperinsulinism. *Eur J Endocrinol*. 2013;168:557-564

