

# Potential effects of endocrine disruption: reproductive tract abnormalities in a 4 year old boy

Cosmina Rimbu<sup>1</sup>, Lisandra Damian<sup>1,2</sup>, Ramona Axinte<sup>1</sup>, Cristina Preda<sup>1,2</sup>, Voichita Mogos<sup>1,2</sup>, Maria Christina Ungureanu<sup>1,2</sup>.

1. Endocrinology Clinic, "Sf. Spiridon" Emergency Clinical Hospital, Iasi, Romania.

2. "Grigore T. Popa", University of Medicine and Pharmacy, Iasi, Romania.


## Introduction:

Endocrine disrupting chemicals are substances, both natural and artificial to which we are all exposed, even in a low dose in our everyday life. Health effects attributed to endocrine disrupting compounds include immune dysfunctions, various cancers, neurological effects and behaviour disorders, reproductive problems, early puberty, etc. Over the past 50 years, an increase in urogenital tract abnormalities in males has been noted.

## Case report:

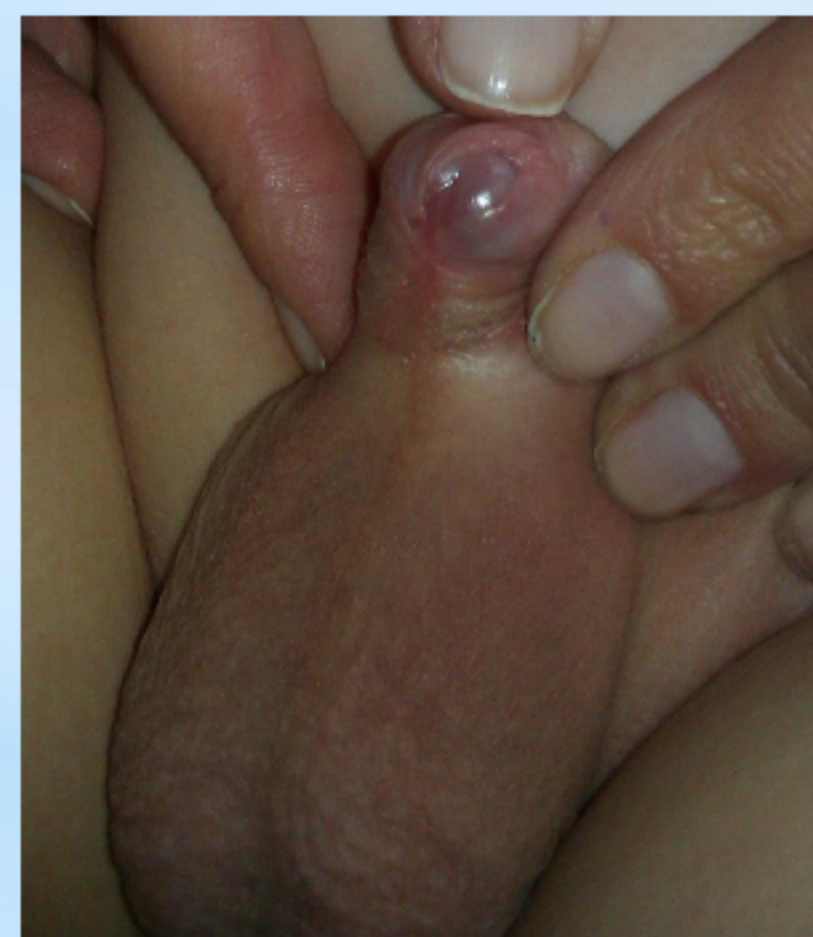We present a **4 year old boy** case, born at term, by caesarean section, addressed to the Endocrinology Department for micropenis, hypospadias and overweight.

**Family history:** Mother was diagnosed with PCOS but she never took anti androgenic treatment before the patient was conceived; she is working in a paint factory.



### Clinical exam :

- height: 109 cm (+ 1 SD),
- weight: 27 kg (+ 3,5 SD),
- micropenis: 3 cm (- 2,5 SD),
- hypospadias,
- bilateral descended testicles,
- normal developed scrotum.



### Workup:

- normal pituitary function with prolactin, cortisol, ACTH, GH, IGF-1, TSH, FT4, FSH, LH – in limits.
- DHEAS slightly increased: 28, 92 ng/dl; repeated :44 ng/dl,
- normal 17OH progesterone: 2,3 ng/ml ( 0,2-3,1),
- normal abdominal, pelvic and testicular ultrasounds,
- normal karyotype.

Late-onset 3 beta-hydroxysteroid dehydrogenase deficiency: excluded - androstendione in limits.

5 alpha reductase deficiency: hCG stimulation: DHT= 252 pg /ml - borderline values, testosterone /DHT= 12,77 infirm this diagnosis.

Androgen partial resistance: the patient has descended testicles; no genetic tests available in our country; good response after androgen treatment.

Intersexuality due to endocrine disruptors.

We took in consideration next **diagnostic assumptions:**

He received treatment with testosterone enanthate 50 mg at 3 weeks, for 3 months, and his penis increased: 5 cm. He grew 9 cm in 9 months and bone age improved. Is scheduled for hypospadias correction intervention.

## Conclusions:

Endocrine disruptor pathology must always remain a diagnostic hypothesis in reproductive tract abnormalities in children.

