

Stress Cardiomyopathy following Radioactive Iodine Therapy: A case report

Authors A Dimakopoulou, K Vithian, D Gannon, A Harkness

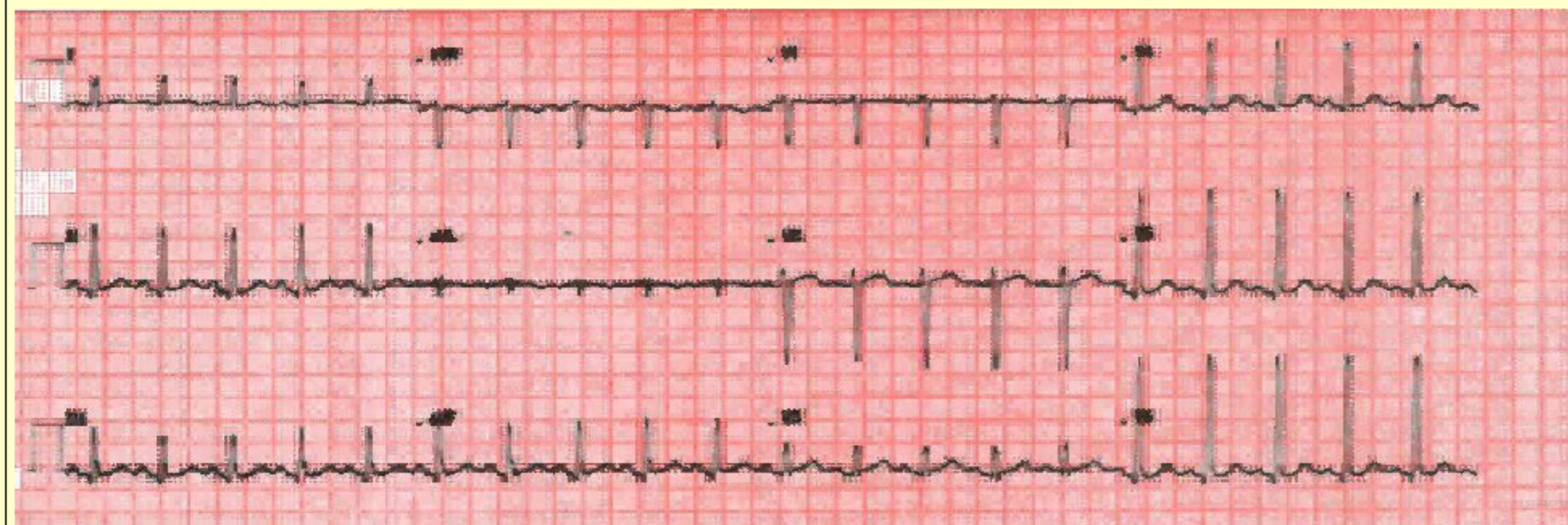
Hospital Colchester Hospital University NHS Foundation Trust, UK

SUMMARY AND BACKGROUND

A 55-year old female presented with Grave's disease and was originally treated with Carbimazole. Radioactive Iodine (RAI) was administered on the basis of relapsed disease and 4 days later, she presented with symptoms suggestive of heart failure. She was biochemically thyrotoxic. Electrocardiography showed borderline ST elevation and Troponin T was significantly elevated. Echocardiography showed apical ballooning and coronary angiography was normal.

Stress (Takotsubo) cardiomyopathy after radioactive iodine is a rare entity – this is the second case report in the literature since 2009. Management is supportive until ventricular function is restored.

Electrocardiography showed sinus tachycardia, 121 per minute, and borderline ST elevation in II/III leads. Troponin T was elevated at 438 ng/L but coronary angiography was normal.



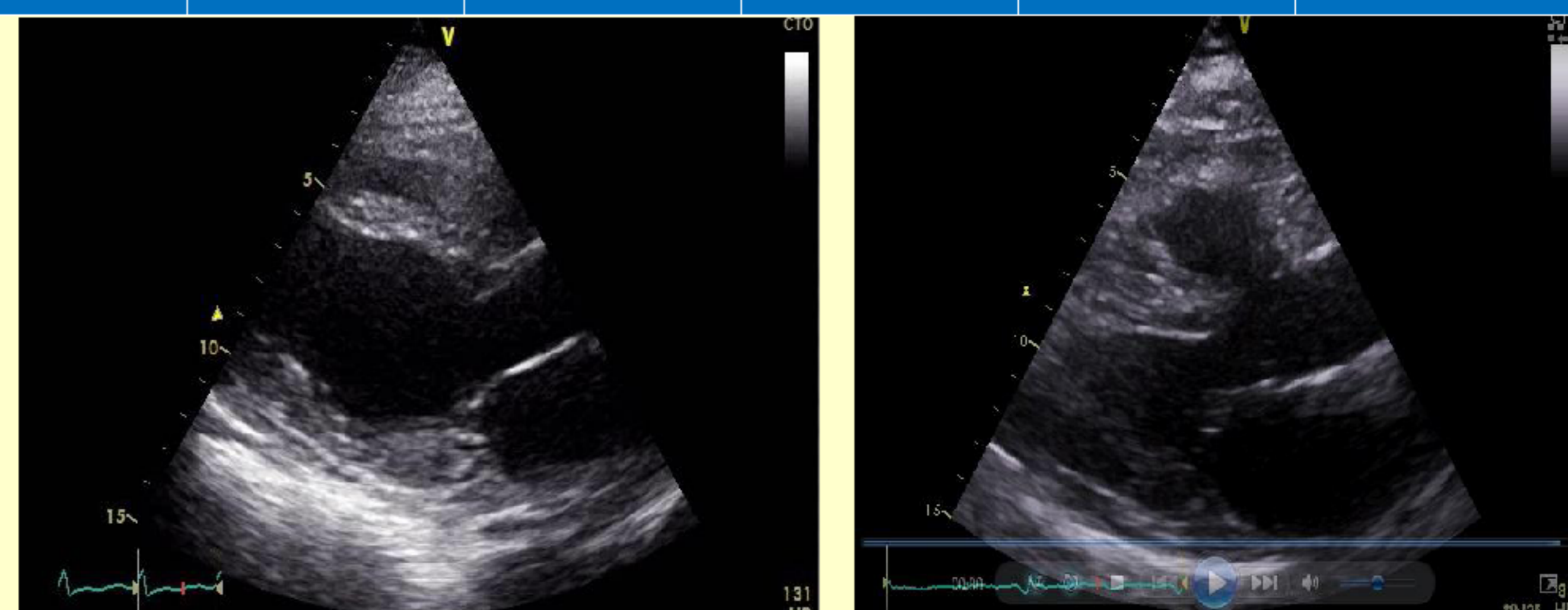
PRESENTATION OF CASE

A 55-year old female was assessed in the endocrine clinic with facial sweating and dry lips. She had no signs of thyroid eye disease or palpitations. There was a multinodular goitre confirmed on thyroid ultrasound. Initial presentation was consistent with subclinical hyperthyroidism. Carbimazole was started a few months later as our patient developed hyperthyroidism.

In an attempt to reduce the dose of Carbimazole, she had an early relapse and Radioactive Iodine (400 MBq) was offered for definitive treatment. Euthyroidism was achieved prior to this. Four days after Radioactive Iodine, she presented at the Emergency Department with chest tightness and dyspnea. There were bilateral crackles on chest auscultation. Thyroid function testing was consistent with thyrotoxicosis.

	Initially	8/12 later	Improve ment	Relapse	Prior RAI	4/7 post RAI	4 /12 post RAI
TSH mu/L	< 0.01	< 0.01	< 0.01	< 0.01	<0.03	<0.01	2.18
fT4 pmol/L	18.6	42.2	18.2	32.8	19.6	77.7	6.2

Parasternal long axis echocardiography showed apical ballooning with EF of 30-35% (Left) that returned to normal (right) after 4 weeks.



MANAGEMENT AND FOLLOW UP

A diagnosis of radiation thyroiditis complicated by stress cardiomyopathy was made. Our patient was treated with Propylthiouracil, Ramipril and Carvedilol. She also completed on an oral course of Prednisolone. Stress cardiomyopathy is a rare but important complication of thyroiditis. Radiation thyroiditis occurs in 1% of patients receiving radioiodine and lasts for a few weeks. This is the second case of stress cardiomyopathy after Radioactive Iodine reported in the literature.

In the first year after Radioiodine therapy patients are at increased cardiovascular risk and that is probably associated with the destruction-mediated release of the thyroid hormone. Our case is an example of the impact that the transient increase in thyroid hormones has on cardiovascular physiology. Excess thyroid hormone results in increased sympathetic tone and tachycardia. Stress cardiomyopathy has previously been linked with acute illness, emotional or physical stress. Pathogenic mechanisms include catecholamine excess, coronary artery spasm and microvascular dysfunction. It is possible that stimulation of the myocardium from thyroid hormones after Radioactive Iodine treatment is accountable for our patient's presentation.

FUTURE CONSIDERATIONS AND CONCLUSIONS

- Inpatient mortality from stress cardiomyopathy ranges from 0 to 8%; patients who survive the acute episode recover to normal LV function within one to four weeks.
- A previous case of Takotsubo (stress) cardiomyopathy in the context of radiation thyroiditis was reported on a 73-year-old man with a history of a toxic multinodular goitre, who was hyperthyroid at the time of Radioiodine treatment. Although our patient received a full 18-month treatment with carbimazole, she presented with post-ablative thyrotoxicosis and stress cardiomyopathy. Risk factors remain unknown.
- The vast majority of cases are in post-menopausal women, where this condition should be considered in acute presentations of infraction or failure.

References

1. Takotsubo cardiomyopathy following radioiodine therapy for toxic multinodular goitre, Van De Donk N.W.C.J, Netherlands Journal of Medicine, November 2009, vol./is. 67/10(350-352), 0300-2977
2. Radioiodine Therapy for Hyperthyroidism, Douglas S. Ross, M.D. N Engl J Med 2011; 364:542-550 February 10, 2011 DOI: 10.1056/NEJMct1007101
3. Thyroid Hormone and the Cardiovascular system, Franklin H. Epstein M.D., N Engl J Med 2001; 344:501-509 February 15, 2001

