



# "Hypercalcemia; A silent indolent course?"

R. Casey, L. Higgins, F. Finucane, M. C. Denny

1. Department of Endocrinology, Galway University Hospital, Galway

## Case

An 83 year old lady presented to hospital with a one week history of malaise, dyspnoea and chest pain. Her admission bloods revealed a markedly elevated calcium of 4.16mmol/L. Further investigations revealed a PTH of >5000ng/L. Clinically the patient had poor dentition which had developed over the past 3 years and a history of episodic abdominal pain and constipation. For investigation of primary hyperparathyroidism, she had an ultrasound neck and parathyroid isotope, which revealed an enlarged 8cm left parathyroid gland. She was initially managed with intravenous bisphosphonate, IV fluids and IV furosemide, once intravascularly volume replete. As part of her initial workup, she underwent a CT pulmonary angiogram. This revealed acute subsegmental pulmonary emboli, a cystic pancreatic lesion, sequelae of previous pancreatitis, nephrolithiasis and possible medullary sponge kidney. Swift surgical referral was sought because of concern of possible parathyroid carcinoma. Once her calcium was optimised and the patient was medically fit, a minimally invasive parathyroidectomy was carried out. Surgical dissection included a sliver of the left thyroid lobe to ensure clear surgical margins with the aforementioned suspicion of a parathyroid carcinoma. The high risk of hungry bones was anticipated and the patient was given vitamin D by intramuscular injection pre operatively and a bed was booked in the high dependency unit post operatively to facilitate an arterial line and frequent close monitoring of ionised calcium levels. Fortunately the patient only required four intravenous infusions of calcium. Within five days of her surgery the patient was discharged. The histology revealed a parathyroid adenoma with no suspicious or mitotic features.

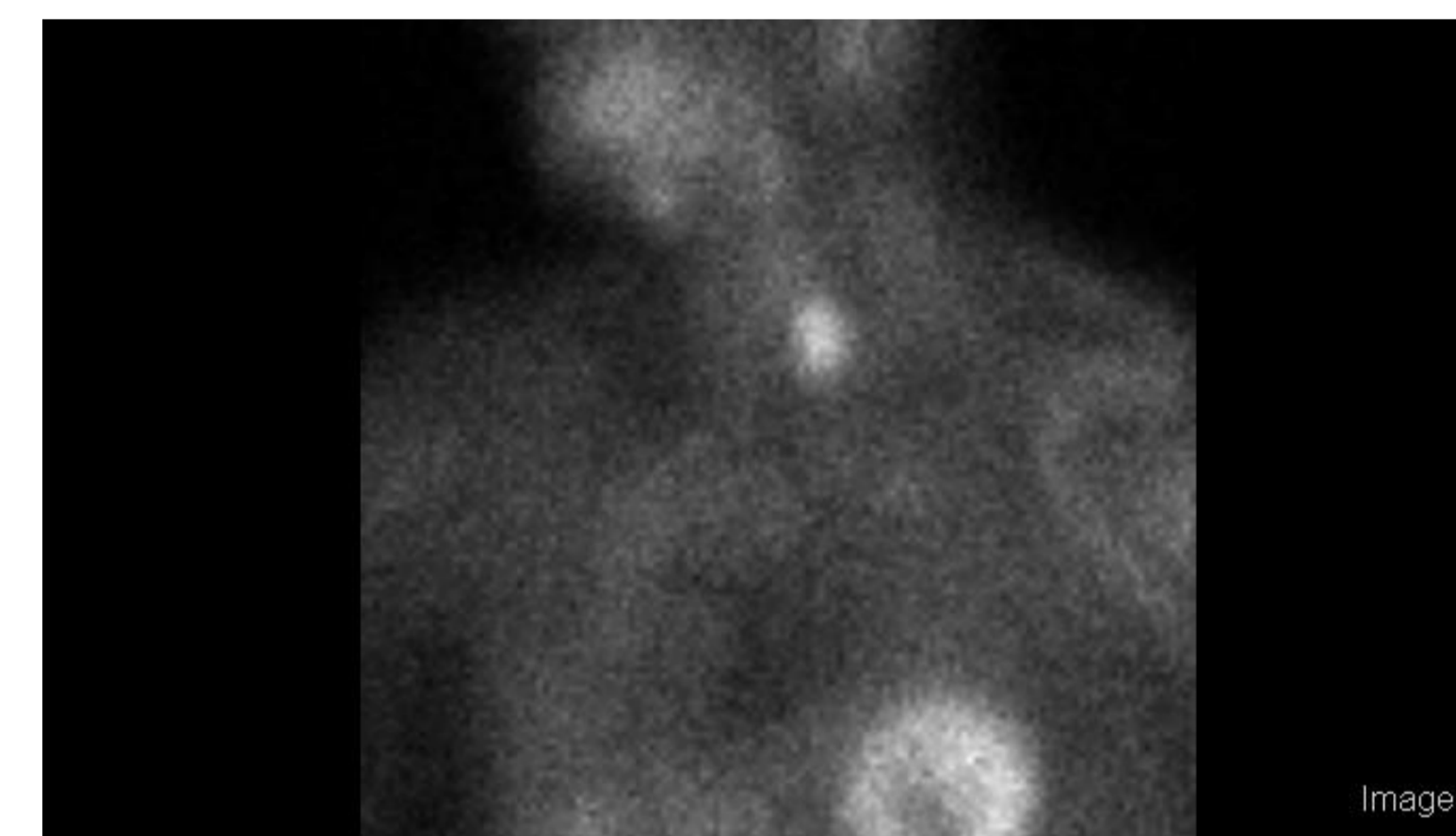
## Discussion

This case highlights the importance of recognising that acute hypercalcemia is a medical emergency requiring immediate treatment and very close monitoring. When hypercalcemia reaches a critical level (>3.00 mmol/L), two organs are at risk for decompensation- the kidneys and the brain, termed a hypercalcemic crisis. (1) Decompensated primary hyperparathyroidism is felt to be commonest entity causing a hypercalcemic crisis. Polyuria may develop into oliguria and finally anuria, especially in case of exsiccosis. If not treated promptly, hypercalcemic renal insufficiency can be fatal. Psychologic disturbances may develop into somnolence and finally coma. Approximately 20 yr ago, there were more reports of hypercalcemic crisis (2). It is evident that the current use of earlier intravenous fluids for critically ill patients and optimized strategies for intensive care medicine have made hypercalcemic crisis a rare event. Fortunately our patient's hypercalcemia was treated efficiently with IV fluids, IV bisphosphonate and IV loop diuretics once she had been rendered intravascularly volume replete.

**Table 1**

<b>PTH</b>	>5000ng/L	<b>Na</b>	138mmol/L
<b>Vitamin D</b>	<15nmol/L	<b>K</b>	3.2mmol/L
<b>Calcium</b>	4.16mmol/L	<b>Cl</b>	98mmol/L
<b>Inorganic Phosphate</b>	0.81mmol/L	<b>Mg</b>	0.81mmol/L
<b>Total Protein</b>	70g/L	<b>Glucose</b>	6.6mmol/L
<b>Albumin</b>	38g/L	<b>Bilirubin</b>	21umol/L
<b>Urea</b>	9.6	<b>ALP</b>	376 U/L
<b>Creatinine</b>	116	<b>ALT</b>	29 U/L
<b>eGFR</b>	39ml/min	<b>GGT</b>	102 U/L
<b>Urine Calcium Excretion</b>	416umol/L	<b>CK</b>	34U/L
<b>Amylase</b>	185 U/L	<b>Troponin</b>	70ng/L

## Images



Isotope parathyroid scan showing a large left sided superior parathyroid adenoma

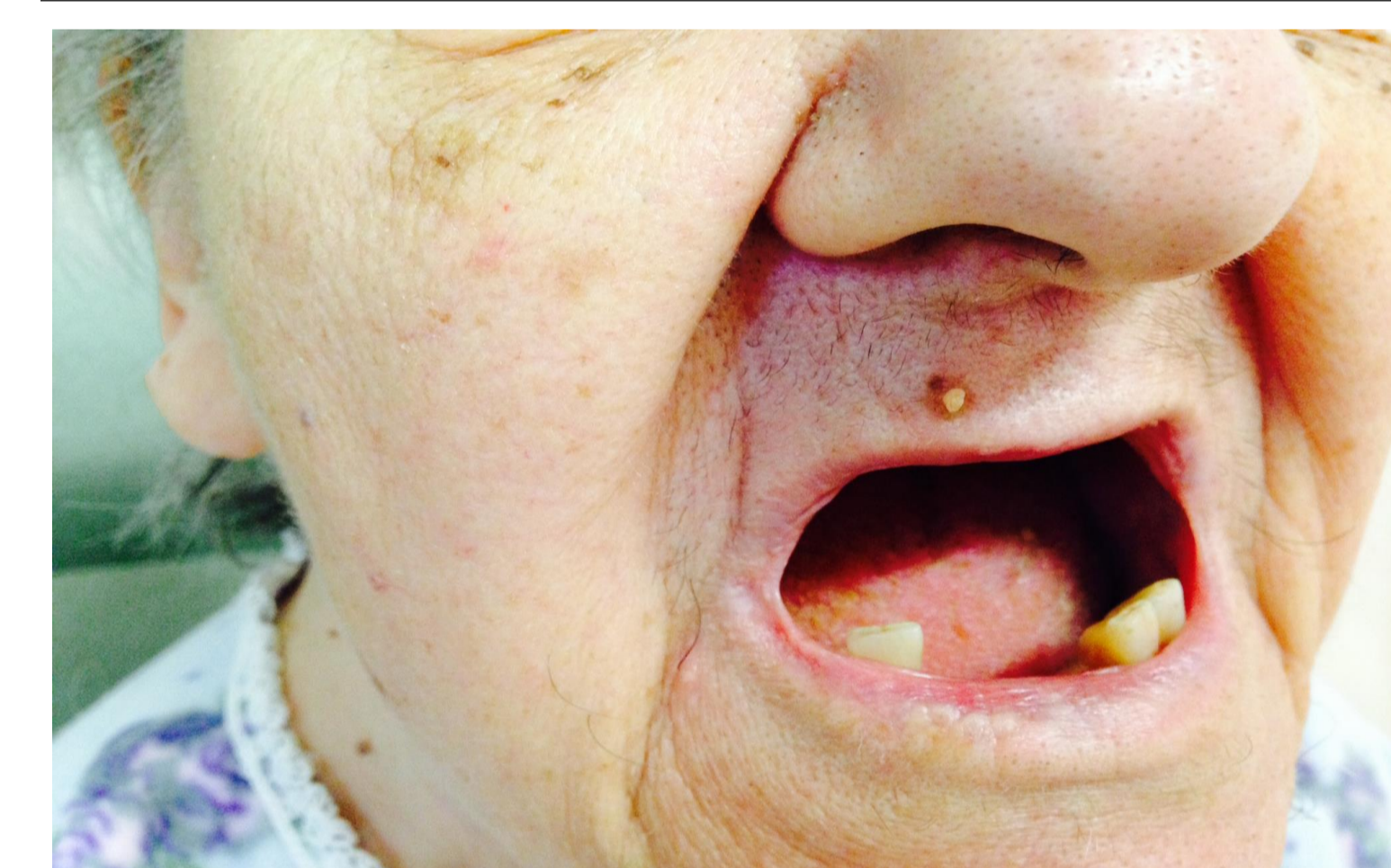
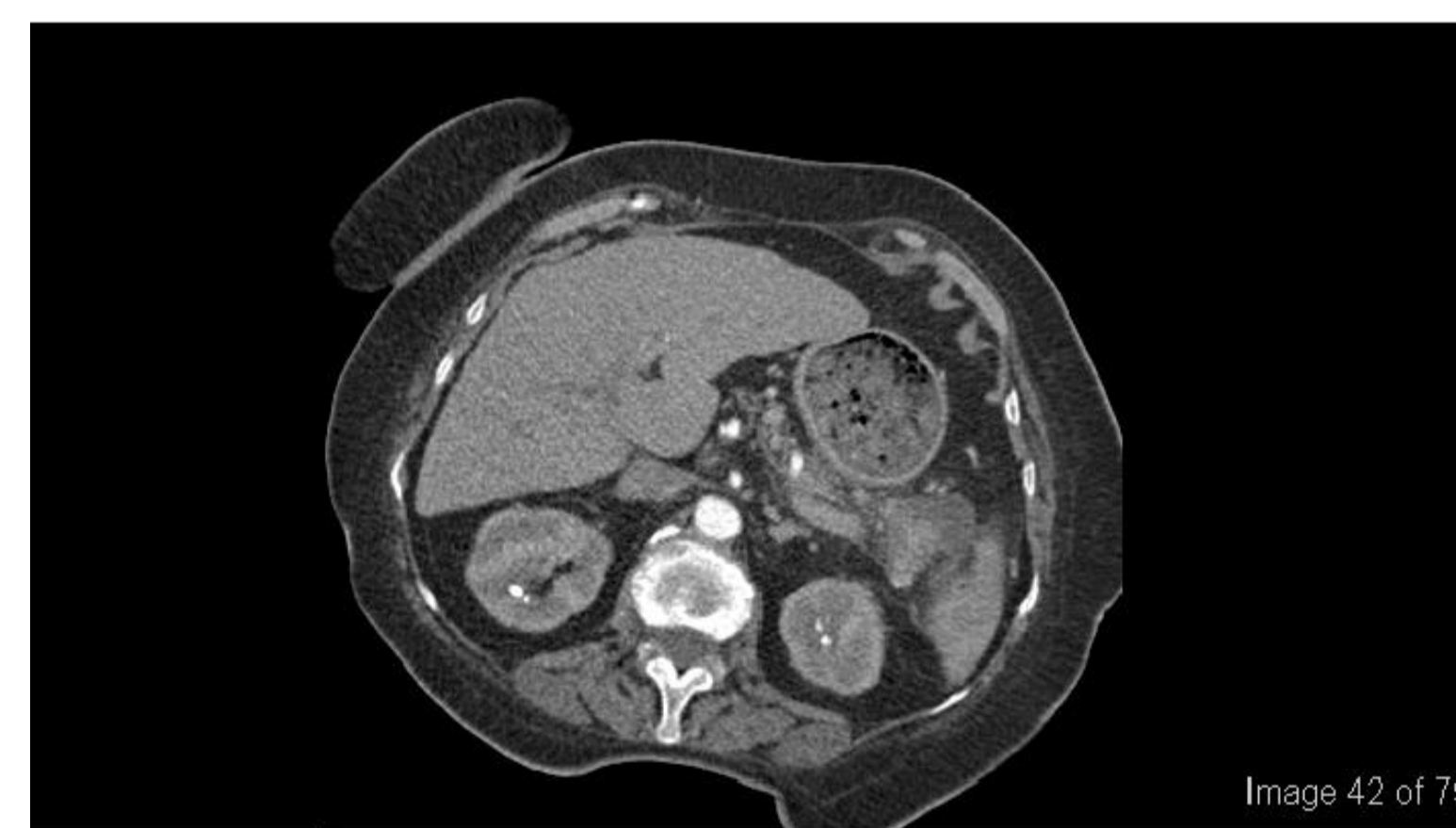
Image of patient showing poor dentition.



CT of abdomen revealing a pancreatic pseudocyst.

## Conclusion

This is a very interesting case of a lady with primary hyperparathyroidism who had likely been hypercalcemic for a significant period of time prior to presentation, as she had developed complications of nephrolithiasis, osteopenia, previous bouts of pancreatitis and tooth resorption. Primary hyperparathyroidism is often felt to be a benign entity for which exists a relatively routine surgical cure. However this case reminds us of the numerous complications induced by hyperparathyroidism and hypercalcemia.

## References

1. JASN February 1, 2001 vol. 12 no. suppl 1 S3-S9.
2. Ann Intern Med 93: 269-272,1980