

EUTHYROID GRAVES' OPHTHALMOPATHY IN A PATIENT WITH LONG-TERM AMIODARONE TREATMENT

Minodora Betivoiu¹, Sorina Martin^{1,2}, Alexandra Nila¹, Simona Fica^{1,2}

1. Elias Hospital, Endocrinology Department

2. Carol Davila University of Medicine and Pharmacy, Endocrinology Department

INTRODUCTION

Ophthalmopathy, the most common extrathyroidal manifestation of Graves' disease, occurs in approximately 5% of cases in the absence of hyperthyroidism.

Amiodarone, an iodine-rich antiarrhythmic drug, influences thyroid function, causing thyrotoxicosis or hypothyroidism, but its effect on thyroid autoimmunity is still a matter of debate.

CASE REPORT

We report the case of a 58-year-old woman, suffering from non-sustained ventricular tachycardia, treated inconsistently with amiodarone for 27 years. Thyroid function was normal until January 2014 when she developed amiodarone induced hypothyroidism (TSH=24mUI/L) with negative thyroid autoantibodies anti-Tg=0.1UI/mL(<4), anti-TPO=1.0UI/mL(<20), and substitutive therapy with levo-thyroxine 50microg/day was started. Three months later the patient stopped levothyroxine at a TSH=0.16mUI/L. Subsequent evaluation in August showed normal thyroid function (TSH=3.4mUI/L).

In October she was referred to our Department for periorbital oedema, increased tearing, diplopia, mild conjunctival injection. The laboratory tests showed euthyroidism (TSH=3.88mUI/L), negative anti-Tg and anti-TPO antibodies, positive TRAb=6.8UI/L (<1). Thyroid ultrasound was normal. The eye examination revealed a clinical activity score of 4, decreased left eye motility, vertical diplopia and Hertel exophthalmometer measurements were 15mm on the right and 17.5mm on the left eye. The orbital CT-scan showed thickening of the left eye inferior and medial rectus muscle.

The patient was treated with 6 pulses of intravenous methylprednisolone, 250mg once a week, but after the third pulse she developed symptomatic bradycardia. The cardiologist recommended to stop amiodarone. The remaining pulses were well tolerated, with improvement of the eye symptoms

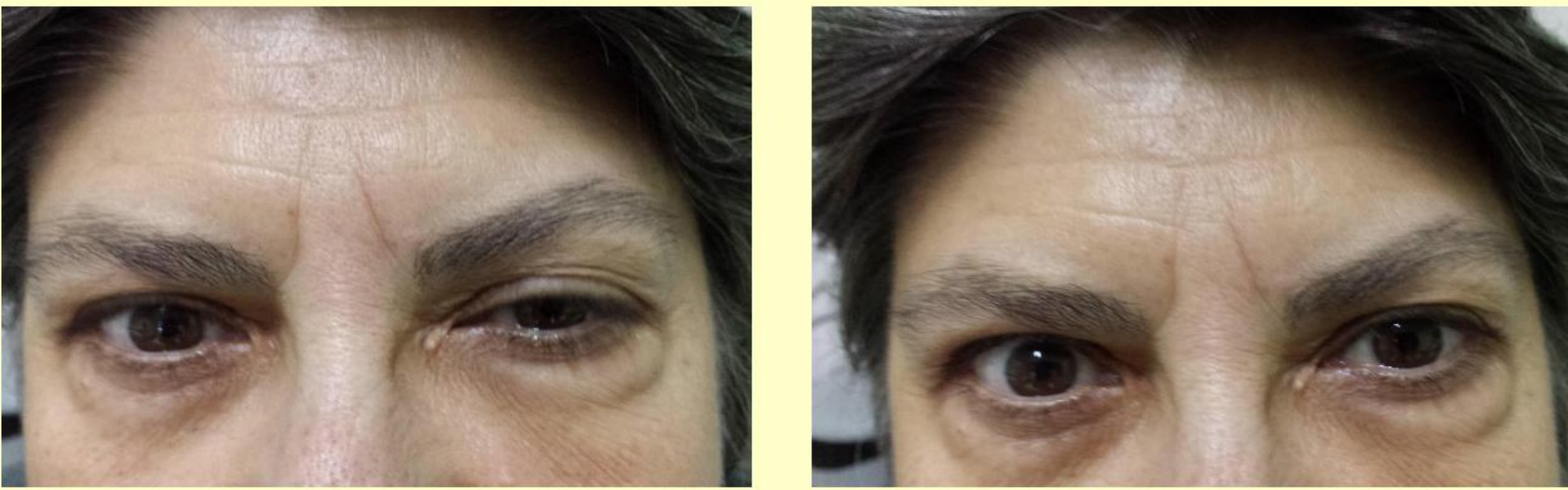


Figure 1, 2. Left eye mild proptosis with periorbital oedema and mild conjunctival injection

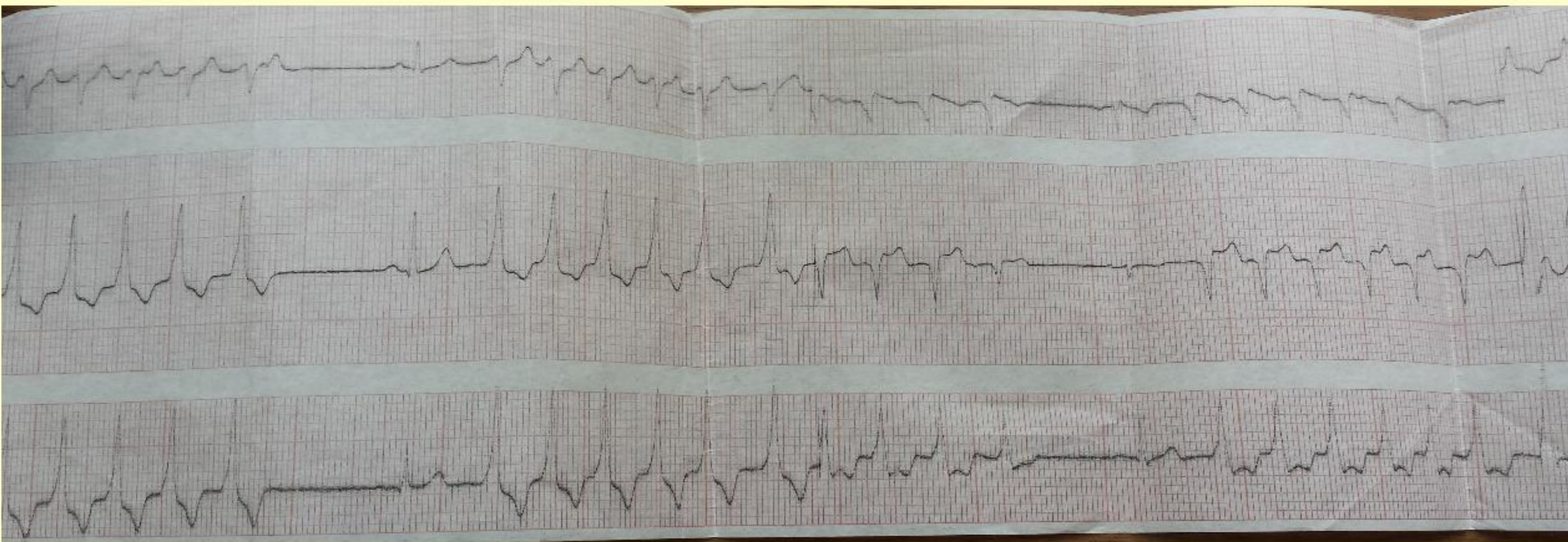


Figure 3. EKG - ventricular tahycardia

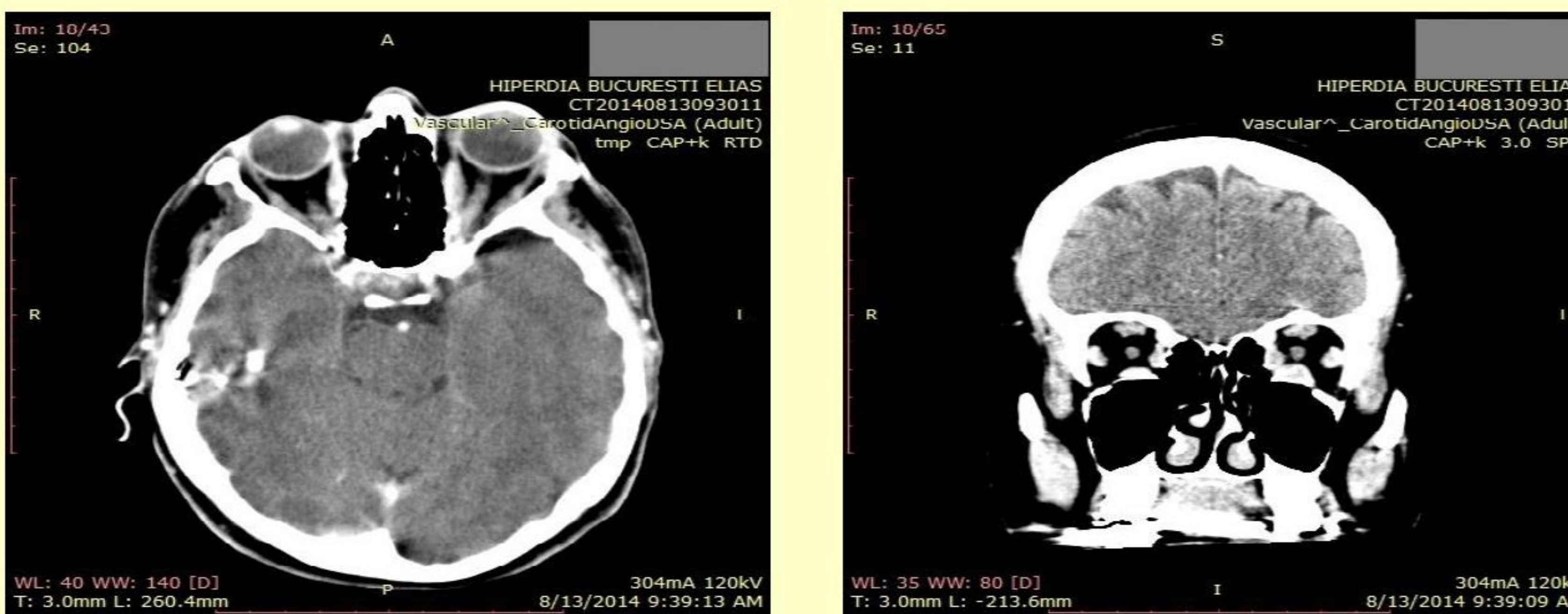

Figure 4,5. Orbital CT - thickening of the left eye inferior and medial rectus muscle

CONCLUSIONS

In our case this variable thyroid status and the occurrence of euthyroid Graves' opthalmopathy sustain the finding that in susceptible individuals amiodarone may precipitate thyroid autoimmunity due to its cytotoxic effect with a greater release of thyroid antigens.

Patients with euthyroid Graves' opthalmopathy need regular follow-up, because the eye involvement may develop before the appearance of clinical or laboratory signs of hyperthyroidism

References

- Subodh Banzal, Abhishek Singhai, Pragya Jain, Euthyroid ophthalmopathy. Thyroid Res Pract, 2013; 10:32-34
- Karin Sundelin, Kerstin Norrsell, Enlargement of extraocular muscles during treatment with amiodarone, Acta Ophthalmol. Scand, 1997; 75:333-334
- Marjorie Safran, Enio Martino, Fabrizio Aghini-Lombardi, Luigi Bartalena, Stefano Balzano, Aldo Pinchera, Lewis E. Braverman, Effect of amiodarone on circulating antithyroid antibodies, BMJ. 1988; 297:456-457

