

An audit of the investigation and management of adrenal incidentalomas



McElwaine FH¹, Ellis PK², Bell PM¹, Courtney CH¹,
Hunter SJ¹, Mullan K¹, McCance DR¹

¹Regional Centre for Endocrinology and Diabetes, Royal Victoria Hospital, Belfast

²Department of Radiology, Royal Victoria Hospital, Belfast

Background

The incidental adrenal mass is a serendipitously discovered adrenal lesion, >1 cm, on radiologic examination done for reasons other than to investigate for primary adrenal disease¹

Excludes:

Imaging done where there is a high suspicion/known malignancy
Clinically evident adrenal disease missed due to insufficient clinical examination

Prevalence of adrenal incidentaloma 1-10%²

- 2-5% adrenocortical carcinoma
- 5.3% subclinical Cushing's syndrome
- 5% clinically silent pheochromocytomas
- 1% primary aldosteronism

Objective

To establish whether adrenal incidentalomas are being investigated and followed up appropriately

Aims

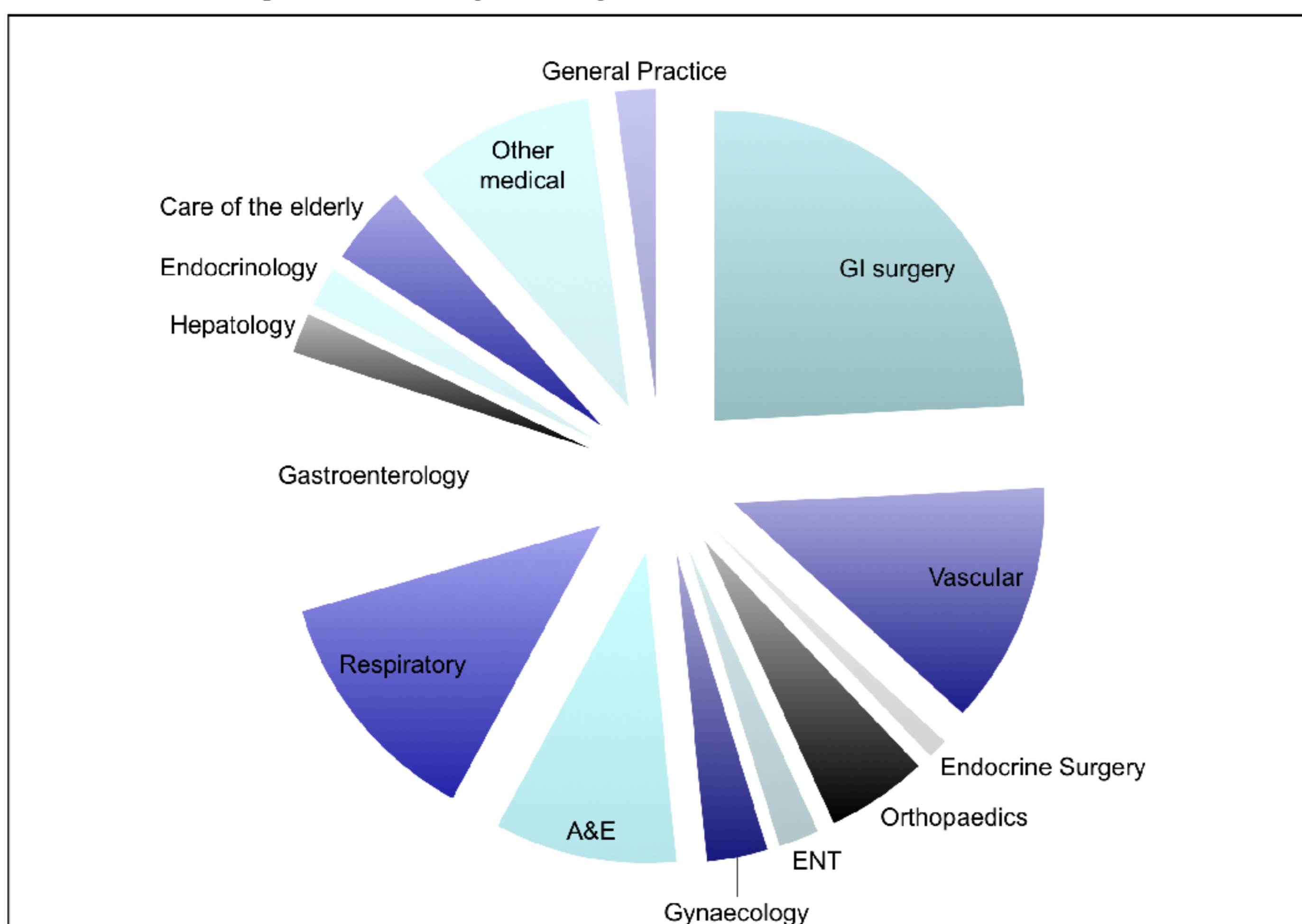
To ascertain whether adrenal incidentalomas being investigated as per American Association of Clinical Endocrinologists guidelines³

- All should be investigated for excess cortisol
- All should be investigated for excess catecholamines
- All hypertensive patients should be investigated for primary hyperaldosteronism
- All >4cm should be considered for surgical resection after hormonal evaluation

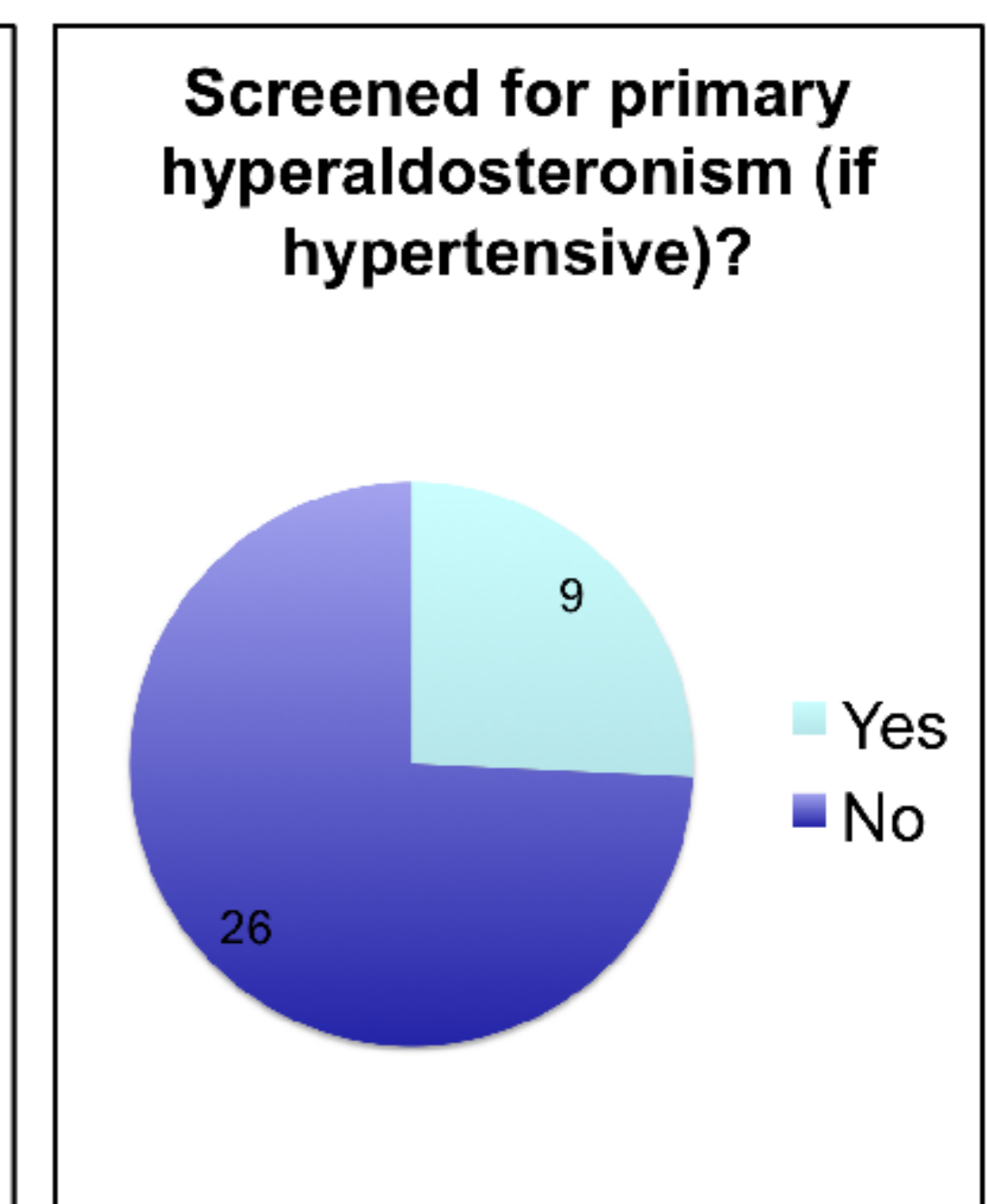
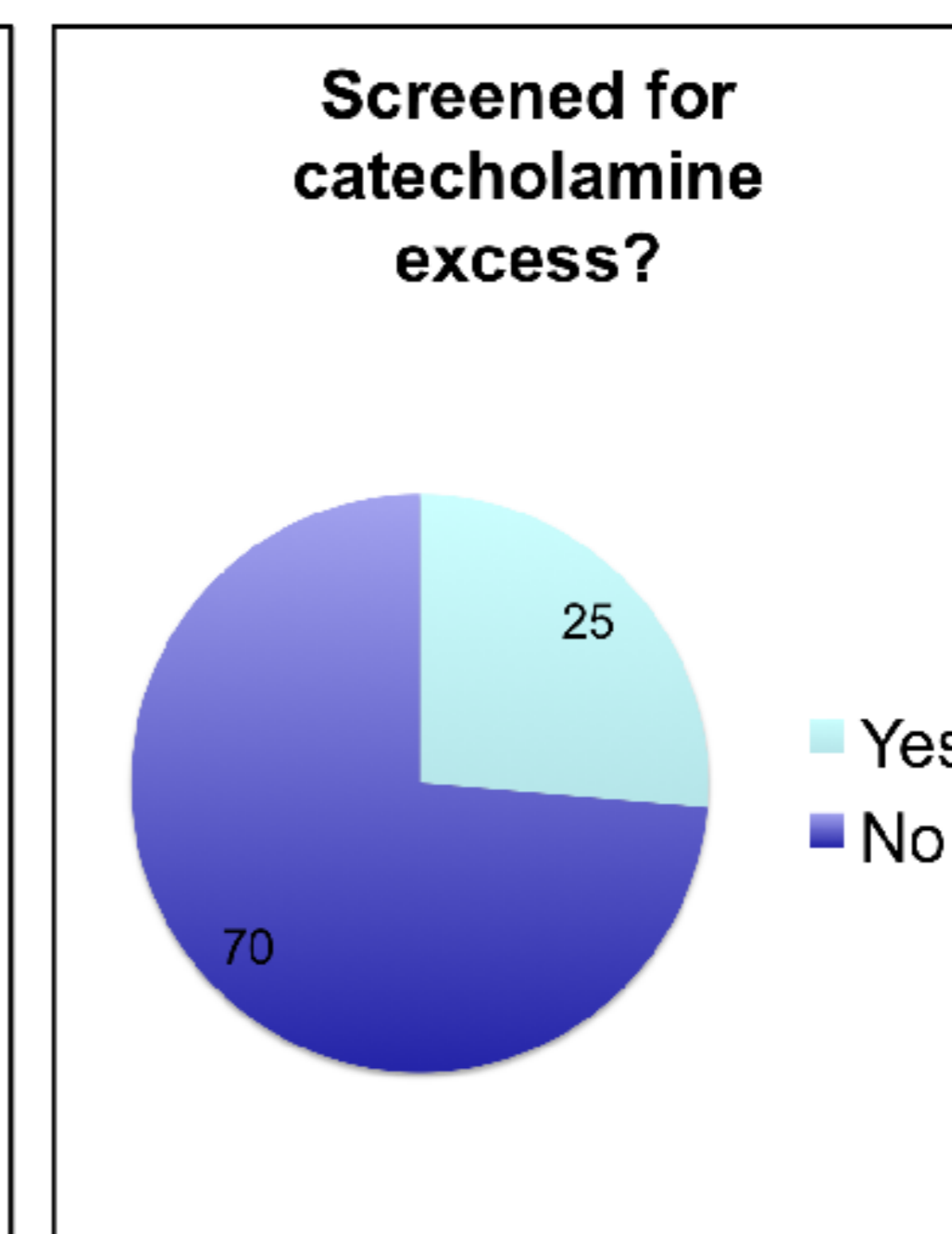
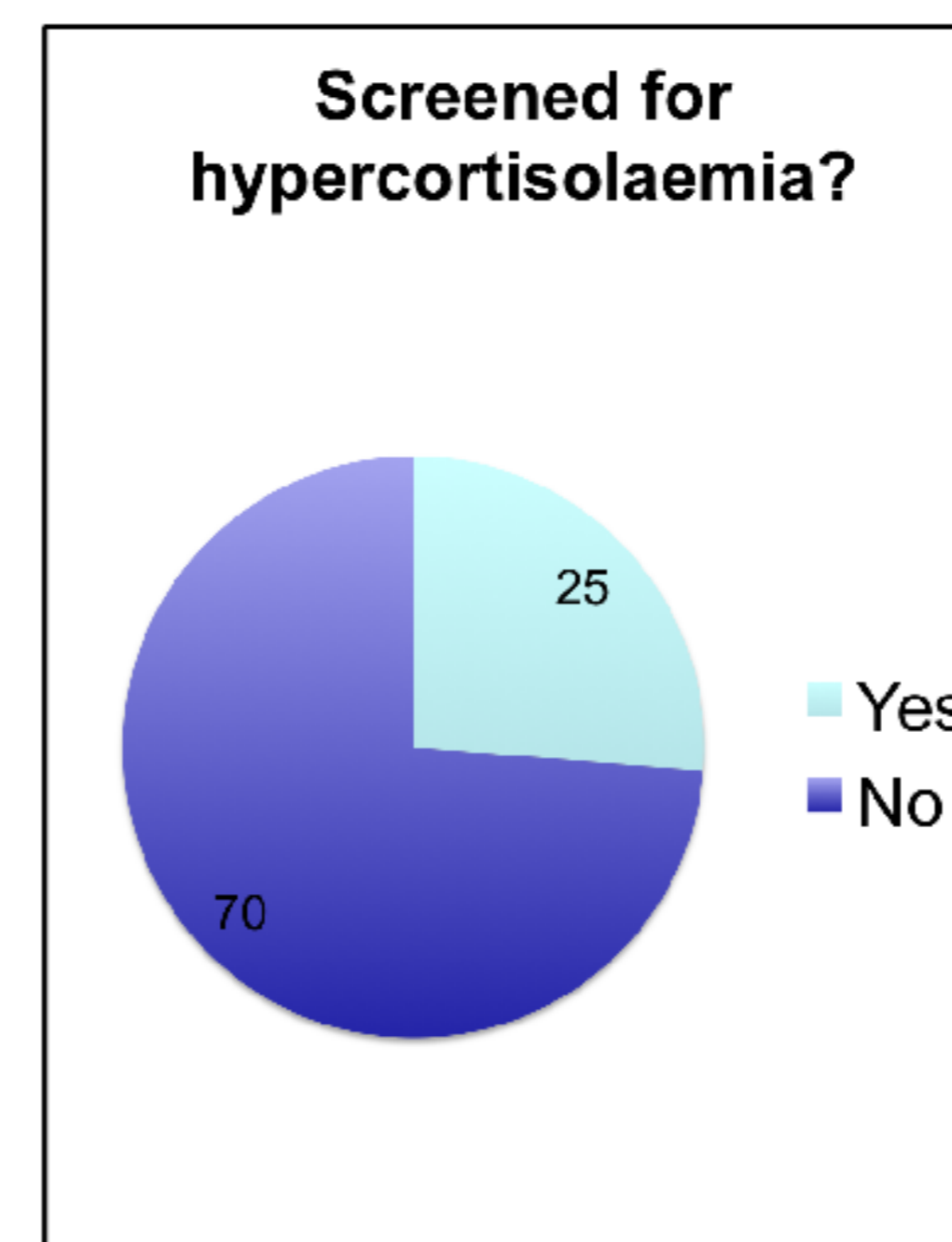
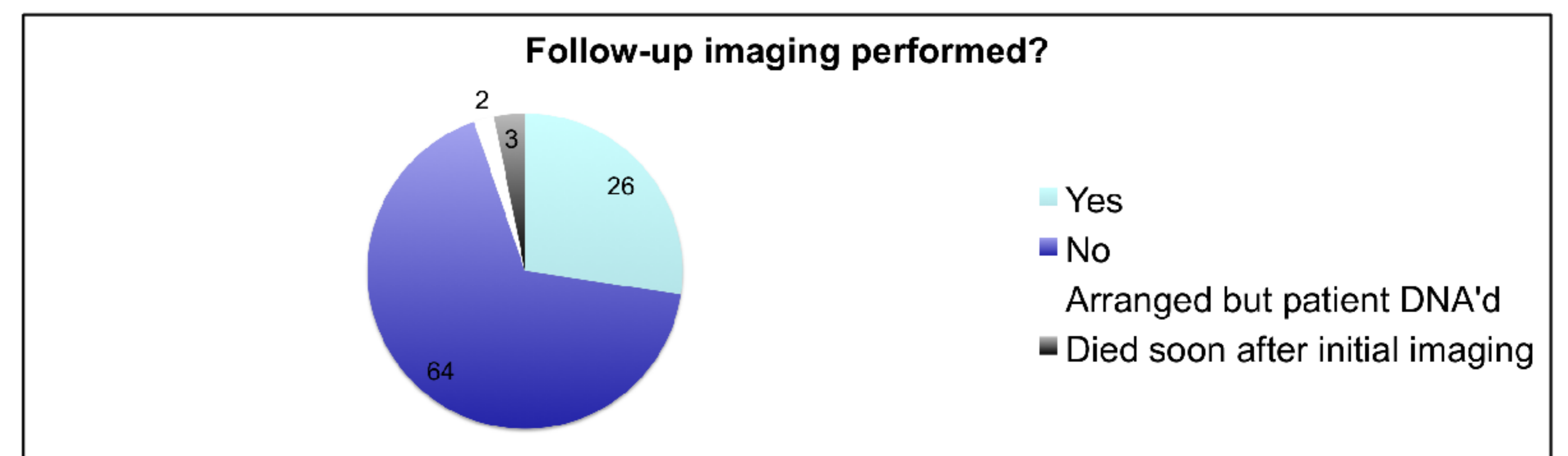
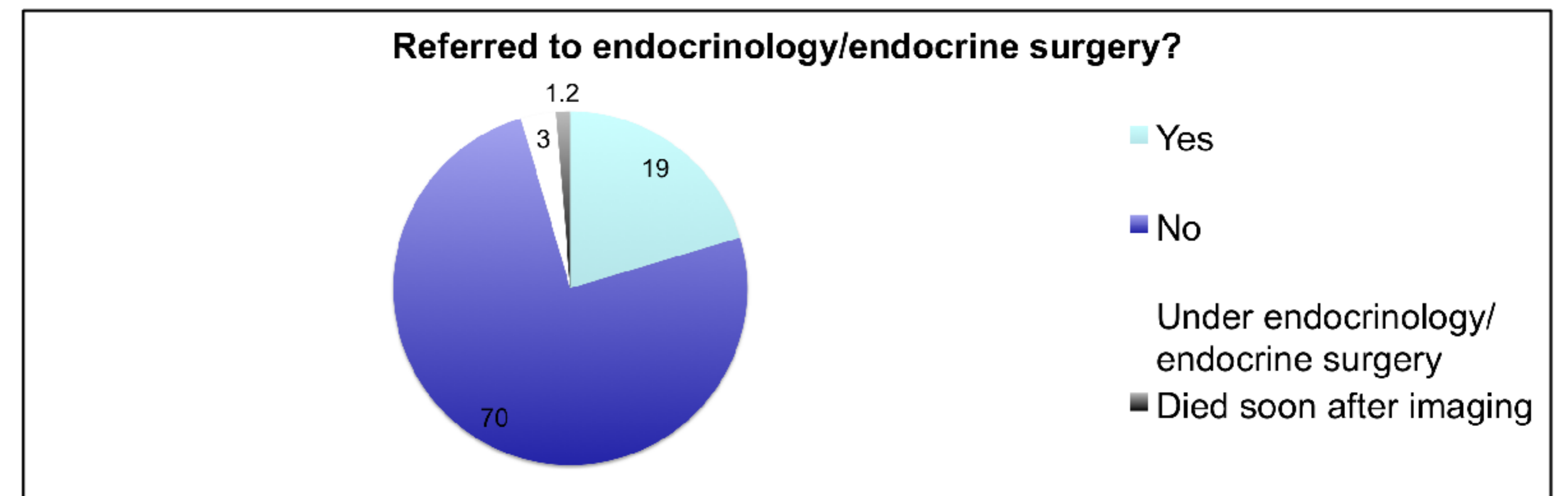
Methods

- All computed tomography (CT) imaging reports containing the words 'adrenal' and 'adenoma' for the year 2010 reviewed
- Reports searched manually, imaging done for cancer screening excluded, imaging done to assess known adrenal lesions excluded
- Clinical information obtained from NIECR (Northern Ireland Electronic Care Record)/clinical notes
- Laboratory information from Belfast Link Labs

Source of patients (n=95)



Results



Summary

- Adrenal incidentalomas frequently ignored by non endocrinologists
- If referred to endocrinology, all investigated appropriately
- If not referred to endocrinology, generally not investigated for hypersecretion
- Serious pathology may be being missed

Recommendations

- Radiology to highlight adrenal lesions >1cm in diameter on imaging reports
- Radiology reports to advise endocrine referral for adrenal lesions >1cm, if clinically appropriate (excluding myelolipomas)

References

1. NIH state-of-the-science statement on management of the clinically inapparent adrenal mass ("incidentaloma") NIH Consens State Sci Statements. 2002;19:1-25.
2. Young, WF. The Incidentally Discovered Adrenal Mass. NEJM. 2007; 356:6
3. AACE/AAES Adrenal Incidentaloma guidelines, Endocr Pract. 2009;15(Suppl 1)