

An incidental diagnosis...

I Khan, P Lambert

Musgrove Park Hospital, Taunton

Introduction

MEN-2a is a rare genetic endocrine disorder associated with mutation of RET oncogene on chromosome 10. It involves lesions in thyroid, parathyroid & adrenal glands. Medullary thyroid carcinoma is the pathological hallmark & usually the first presentation of this rare syndrome. Demonstrating RET mutation is of paramount importance for both patients & their families.

CASE HISTORY

A 64 year old lady with IHD & hypercholesterolemia was referred to Endocrine clinic after she was incidentally found to have high Calcium (3.06) & inappropriately high PTH (18.4) confirming the diagnosis of primary hyperparathyroidism. The lady did not have a previous history of any endocrine problems & her BP was well controlled with Atenolol & Lisinopril. Fortunately the ultrasound neck & SISTRAMIBI scan were both concordant pointing towards a right lower parathyroid adenoma & she was referred to ENT surgeon for minimal invasive parathyroidectomy. Intraoperatively, the surgeon noticed a

firm suspicious looking nodule in the thyroid & took a FNA sample which was later reported Thy 3 follicular lesion. The case was discussed in thyroid surgery & Endocrine MDT & decision of performing right hemithyroidectomy was made to which the patient agreed. The histopathology of the right lobe of thyroid showed that the large palpable nodule was actually benign but it incidentally showed a <1mm papillary carcinoma & approximately 1.5mm medullary carcinoma. Subsequent CT-CAP did not show any lesions in the adrenal gland or the sympathetic tract. Two 24 hour urinary samples for catecholamines have been reported as normal. Results of Calcitonin, CEA & genetic screening for RET mutation are yet awaited.

IMPRESSION

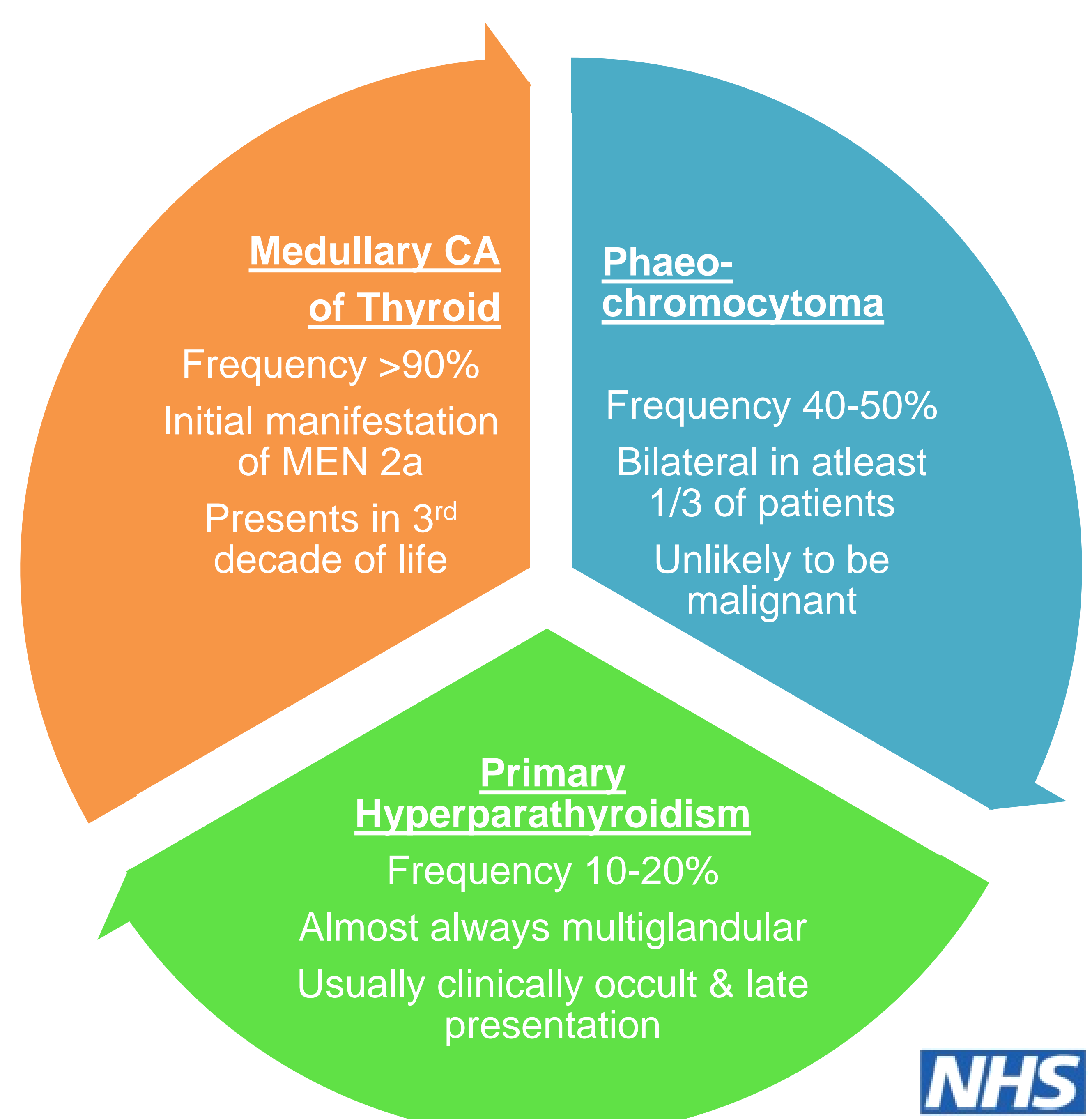
The presence of medullary thyroid cancer & primary hyperparathyroidism raised the possibility of MEN 2a

DISCUSSION

If the RET gene mutation is positive, it would make this an unusual presentation of MEN-2a because of:

- Late presentation (usually presents in 3rd decade)
- Unusual 1st presenting problem (usually MTC)

Clinical Features & Manifestations of MEN 2a



References:

Raue F, Frank-Raue K, Grauer A. Multiple endocrine neoplasia type 2. Clinical features and screening. *Endocrinol Metab Clin North Am* 1994; 23:137
[American Thyroid Association Guidelines Task Force, Kloos RT, Eng C, et al. Medullary thyroid cancer: management guidelines of the American Thyroid Association. *Thyroid* 2009; 19:565](#)