

# TORSADE DE POINTES CAUSED BY GLUTEN-SENSITIVE ENTEROPATHY LEADING TO MULTIPLEX ENDOCRINE FAILURE - A CASE REPORT



Éva Csajbók\*, Andrea Orosz\*\*, Peter Hankovszky\*\*\*, László Rudas\*\*\*, Csaba Lengyel \*\*

\*University of Szeged, 1st Department of Internal Medicine, Endocrine Unit, Hungary

\*\* University of Szeged, Department of Pharmacology, Hungary

\*\*\*University of Szeged, Department of Anaesthesiology and Intensive Therapy, Hungary

## Abstract

A 55 year-old man was brought to the emergency room because of hypotension, fatigue, fever and pain in the left shoulder. Glucose, sodium and potassium levels were normal in the blood. ECG showed 65/min sinus rhythm with negative T waves in the precordial leads. Blood pressure was 70/50 mm Hg. Suddenly **torsade de pointes ventricular tachycardia (TdP)** occurred, which was converted to sinus rhythm with 300 mg amiodarone.

**Coronarography** showed no significant stenosis on epicardial coronaries. During the intervention, supraventricular tachycardia occurred for 30 s and disappeared after 150 mg amiodarone, ECGs showed no PQ prolongation, 76/min sinus rhythm and diffuse T-wave depression.

**Echocardiography** found EF 38%, anterior, inferior, septal akinesis. On the 4th and 7th day of observation 35/min bradycardia occurred with junctional and ventricular extrasystole requiring defibrillation with 200 J. TSH measurement suggested **hypothyroidism** (TSH: 13.89 mIU/l), severe hypocalcaemia suggested **hypoparathyroidism**. Serum total calcium level was: 1.82 mM/l, PTH: 1.5 pM/l. Low serum hydrocortisone value revealed **adrenal insufficiency**.

As the suggested diagnosis was polyglandular autoimmune syndrome, we performed autoimmune screening and found **anti-transglutaminase antibodies**. However, *further autoimmune screening showed no sign for other autoimmune diseases*. Gluten-free diet, hydrocortisone, levothyroxine, calcium, vitamin D3, and testosterone supplementation started, ICD was implanted. TdP never occurred again. Last results showed normal Ca, TSH, FT3, FT4 values, mildly lower testosterone, suppressed ACTH and mildly elevated cortisol levels.

**Conclusion:** We found gluten-enteropathy caused persistent polyglandular endocrine failure leading to torsade de pointes tachycardia requiring reanimation and ICD implantation without having autoimmune origin.

## Case description

A 55 year-old man was brought to the emergency room because of hypotension, fatigue, fever pain in the left shoulder.

### Previous medical history

He suffered from recurrent arrhythmias in the last 5 years, but no alteration was found during the cardiological evaluation. No medication was taken.

**Holter ECG** showed the following results: VES: total: 669, isolated: 633, coupled: 17, SVES: 142, isolated: 63, coupled: 38. Maximum HR: 132, minimum HR: 47 s, fibrillation: 0, s run: 0.

**Echocardiography** proved normal dimensions and ejection fraction (75%).

**Laboratory test** showed normal serum Na<sup>+</sup>, K<sup>+</sup>, UN, kreatinin levels and liver function although Hb was low (115 g/l).

**Gastrosocopy** found antral gastritis without any sign of Helicobacter pylori infection.

**Stress 99Tc myoview** was negative with LVEF: 44%

### 5 years later in the emergency room:

**Laboratory test** showed normal blood glucose (BG): 4.7, sodium (Na<sup>+</sup>): 132 mM/l, potassium (K<sup>+</sup>): 3.2 mM/l levels.

**ECG:** 65/min sinus rhythm with negative T waves in the precordial leads. Blood pressure (BP) was 70/50 mm Hg.

After infusion of 5% glucose and 2 mg MgSO<sub>4</sub> and 2 g KCl **TdP** occurred, which was converted to sinus rhythm with 300 mg amiodarone administration.

**Coronarography** was performed and showed no significant stenosis on epicardial coronary arteries. During the intervention supraventricular tachycardia occurred for 30 s, and disappeared after administration of 150 mg amiodarone. In the Intensive Care Unit ECGs showed no PQ prolongation, with 76/min, sinus rhythm and diffuse T-wave depression. Amiodarone was given 200 mg BID.

**Echocardiography** showed EF 38%, TI II, MI: I. anterior, inferior, septal akinesis. Ao: 30 mm, LA: 44. LV VD: 54, LV VS: 43, IVS: 10, PW: 10 mm.

**On the 4th day** 35/min. bradycardia occurred with junctional and ventricular extrasystolia.

**On the 7th day** of observation he needed defibrillation with 200 J because of ventricular fibrillation.

**On the 8th day** TSH measurement suggested **hypothyroidism** (TSH: 13.89 mIU/l, normal: 0.4-4.2 mIU/l), severe hypocalcaemia suggested **hypoparathyroidism**. Serum total calcium level was: 1.82 mM/l (normal: 2.2-2.5), PTH: 1.5 pM/l (normal: 1.6-6.9).

Serum cortisol measurement showed very low level suggesting **hypoadrenia** (8h: 4 nm/l, normal: 171-536 nm/l, low FT3: 1.6 pm/l (normal: 3.1-6.8, ft4: 4.7 pm/l (normal: 12-22 pm/l), low testosterone: 0.43 nm/l (normal: 9.9-28 nm/l).

We found normal SHBG, FSH, LH and PRL levels: SHBG: 49.3 nM/l (normal: 14.5-48.4), FSH: 2.1 (normal: 1.5-12.45) IU/l, LH: 1.9 IU/L (normal: 1.7-8.6), PRL: 191 mIU/L (normal: 86-324).

As the suggested diagnosis was polyglandular autoimmune syndrome, we performed *autoimmune screening* and found **anti transglutaminase antibodies** (IgA: 15 IU/m /norm:-10 U/ml). ANA screen, anti-SS-A, anti-SS-B, anti Scl-70, anti-Jo-1, anti-Sm/RNP, anti-RNP-70, anti-Sm, anti-centromer-B, anti-dsDNS, anti- annexin IgM/IgG, anti-cardiolipin IgG/IgA/IgM, anti-B2glycoprotein IgG/IgM/IgA, parietal cell antibody was negative. Further investigation excluded the Hashimoto's thyroiditis (anti TPO: 12.19 IU/ml normal) and anti adrenal antibody was negative as well.

**Gluten-free diet was introduced, hydrocortisone, levothyroxin, calcium, vitamin d3, testosterone supplementation started, ICD was implanted. TdP never occurred again.**

**After 12 month of treatment** and gluten-free diet we tried to stop the hormone supplementation because of the negative screening for polyglandular autoimmune syndrome, but hypoadrenia, hypogonadism and hypothyroidism occurred again despite the strict gluten-free diet. **ACTH stimulation test** showed low cortisol levels: 4-20-36-37 nM/l.

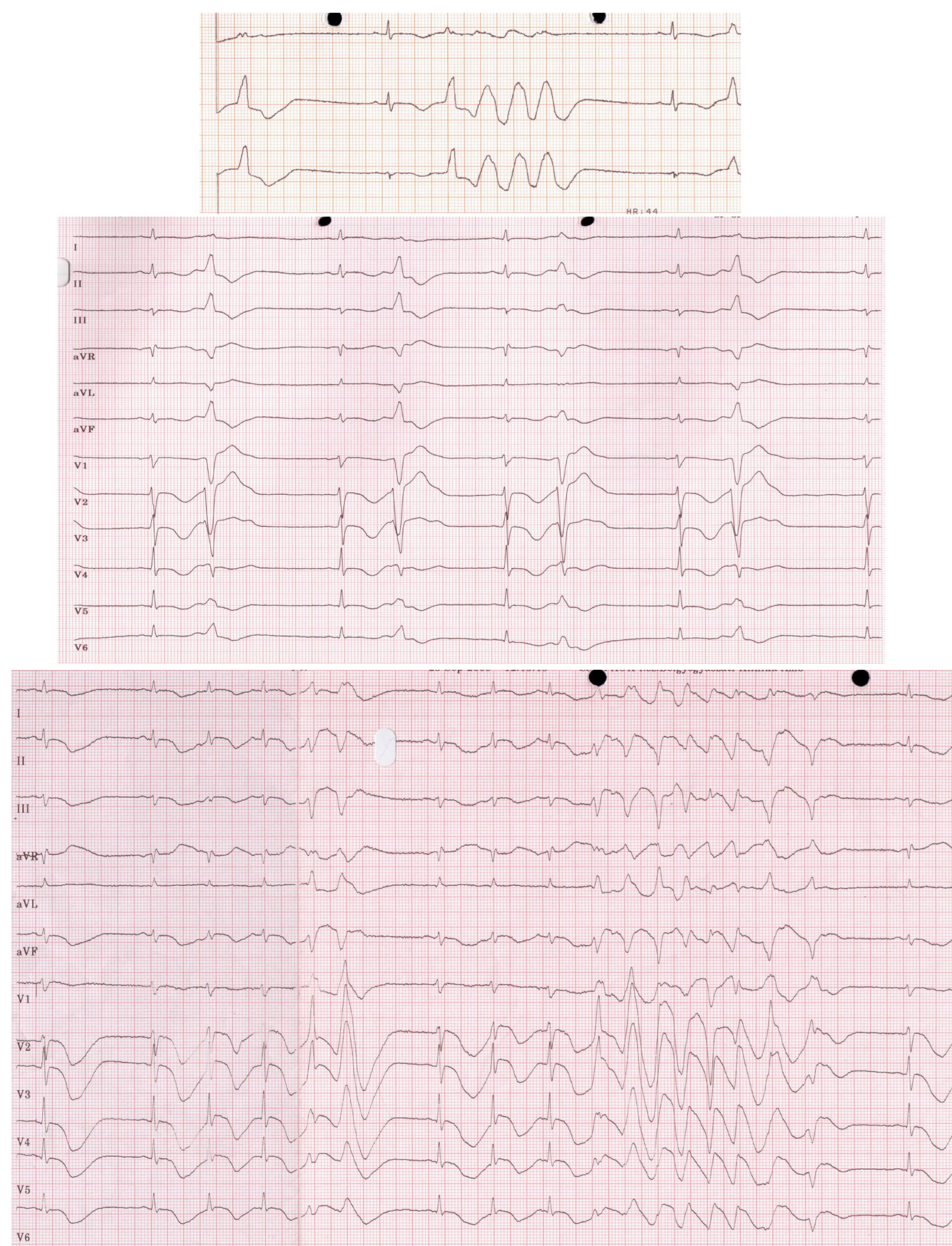
We restarted treatment with 75 ug levothyroxin/day, 15 mg hydrocortisone /day, 600 mg/day calcium citrate, 1 ug alfalcidol. The patient denied the androgene use.

With this treatment, the last results (2 years) showed normal Ca<sup>+</sup>, FT3, FT4, lower testosterone levels, suppressed ACTH, mildly elevated cortisol levels: Ca<sup>+</sup>: 2.42 mM/l, ft4: 20.5 pM/l, testosterone: 5.66 nM/l, ACTH: 0.2 pM/l (normal: 1.6-13.9 pM/l), cortisol: 651 nM/l.

## Conclusion:

**We found gluten-enteropathy caused persistent polyglandular endocrine failure leading to torsade de pointes tachycardia requiring reanimation and ICD implantation without having autoimmune origin.**

**There is no other patient mentioned in the literature with similar cause of torsade de pointes.**



	ER (torsades)	Endocrine	Follow-up (2 year)	Reference ranges
Na <sup>+</sup> (mM/l)	132	133	143	136-145
K <sup>+</sup> (mM/l)	3.2	4.7	4.5	3.5-5.1
Ca <sup>+</sup> , total (mM/l)	<b>1.82</b>	2.36	2.3	2.2-2.55
Haematocrit (L/L)	0.31	0.41	0.39	0.39-0.55
TSH (mIU/l)	<b>13.89</b>	0.28	3.03	0.4-4.2
FT4 (pM/l)	<b>6</b>	20.5	21-4	12-22
Cortisol (nM/l)	<b>4</b>	100	651	171-536
ACTH (pM/l)	-	1.07	0.22	1.6-13.9
PTH (pM/l)	<b>1.5</b>	-	<b>1</b>	1.6-6.9
FSH (IU/l)	2.1	3.1	1.9	1.5-12.45
LH (IU/l)	1.9	2	3.1	1.7-8.6
Testosterone (nM/l)	<b>0.43</b>	1.1	13.01	9.9-28
SHBG (nM/l)	49.3	36.4	52	14.5-48.4
Maintenance therapy (daily)		3x10 mg hydrocortisone 2x0.25 mg fludrocort 3x200 mg Ca citrate 2x1 ug αD3 50mg testo gel 75 ug LT4	10-5 mg hydrocortisone 3x200 mg Ca citrate 1 ug αD3 75 ug LT4	

## Background

**Torsade de pointes** is an uncommon and distinctive form of polymorphic ventricular tachycardia (VT) characterized by a gradual change in the amplitude and twisting of the QRS complexes around the isoelectric line

It is often associated with a prolonged QT interval, which may be congenital or acquired.

Torsade usually terminates spontaneously but frequently recurs and may degenerate into ventricular fibrillation.

In torsade, the morphology of the QRS complexes varies from beat to beat. The ventricular rate can range from 150 beats per minute (bpm) to 250 bpm.

The original report described regular variation of the morphology of the QRS vector from positive to net negative and back again.

The definition also requires that the QT interval be increased markedly (usually to 600 msec or greater).

Torsade usually occurs in bursts that are not sustained; thus, the rhythm strip usually shows the patient's baseline QT prolongation.

The etiology and management of torsade are, in general, quite different from those of garden-variety VT. Differentiating between these entities, therefore, is critically important.

## References

- Kandan SR, Saha M.: Severe primary hypothyroidism presenting with torsades de pointes; BMJ Case Rep. 2012 Sep 17;2012. doi:pii: bcr1220115306. 10.1136/bcr.12.2011.5306.
- Sauer AJ, Newton-Cheh C.: Clinical and genetic determinants of torsade de pointes risk; Circulation. 2012 Apr 3;125(13):1684-94. doi: 10.1161/CIRCULATIONAHA.111.080887. Review.
- Sharma S, Gulati S.: The ketogenic diet and the QT interval; J Clin Neurosci. 2012 Jan;19(1):181-2. doi: 10.1016/j.jocn.2011.05.012.
- Pecori Giraldi F et al: High prevalence of prolonged QT interval duration in male patients with Cushing's disease; Exp Clin Endocrinol Diabetes. 2011 Apr;119(4):221-4. doi: 10.1055/s-0031-1271628.
- Kornelius E, Chen KS, Yang YS, Huang CN.: Torsade de pointes—a rare presentation of primary hyperaldosteronism; Am J Emerg Med. 2012 Jan;30(1):257.e5-7. doi: 10.1016/j.ajem.2010.10.026.
- Michiels V, Miljoen H, Vrints C.: 8. Gastroenteritis with severe consequences: a case of sotalolol-induced torsades de pointes; Acta Cardiol. 2009 Dec;64(6):839-42.
- Yang PC, Kurokawa J, Furukawa T, Clancy CE.: Acute effects of sex steroid hormones on susceptibility to cardiac arrhythmias: a simulation study; PLoS Comput Biol. 2010 Jan 29;6(1):e1000658. doi:10.1371/journal.pcbi.1000658.
- Facenda M, Romero-Garrido R, Hernández-Afonso J, Ramos-López M. 8. Torsade de pointes with a long-QT interval and an empty sella turcica; Rev Esp Cardiol. 2009 Oct;62(10):1195-7.
- Crawford EJ, Cochran D.: Recurrent torsades de pointes in association with a very low calorie diet; Anaesthesia. 2009 Aug;64(8):903-7. doi: 10.1111/j.1365-2044.2009.05940.x.
- Methe H, Hinterseer M et al.: Torsades de Pointes: a rare complication of an extra-adrenal pheochromocytoma; Hypertens Res. 2007 Dec;30(12):1263-6. doi: 10.1291/hypres.30.1263.

**Contact:** Eva Csajbók, MD; 1st Dept. of Internal Medicine, University of Szeged, Hungary.

**Correspondence:** [ecsajbok@freemail.hu](mailto:ecsajbok@freemail.hu)