

A Case of Hypocalcaemia in Ectopic ACTH Production

M Thida, S Drake, R Murray, A Abbas

Department of Endocrinology, The Leeds Teaching Hospitals NHS Trust, Leeds, UK

Background

We describe a patient with profound and resistant hypocalcaemia in the setting of ectopic ACTH production.

Clinical presentation

A 70 year old female presented with general lethargy and a two day history of painful muscle twitching and paraesthesia in her right hand. Past medical history included hypertension, hypothyroidism and she had recently been diagnosed with type 2 diabetes. Examination was unremarkable.

The overall biochemical picture was that of a hypokalaemic alkalosis with hypocalcaemia and hyperglycaemia. Venous gas showed a metabolic alkalosis (pH 7.51, HCO₃ 32.4). CXR revealed a mass at the superior aspect of the right hilum.

Investigation Results

Sodium	140 mmol/l
Potassium	2.9 mmol/l
Urea	8.9 mmol/l
Creatinine	51 umol/l
Corrected calcium	2.05 mmol/l
Albumin	31g/l
Phosphate	0.64mmol/l
Magnesium	0.89 mmol/l
ALT	61 IU/l
ALP	252 IU/l
Random Glucose	21.4 mmol/l
HbA1C	66 mmol/mol
PTH	53.2 pmol/l
24 Hr urinary calcium	3.97 mmol/day (2.5-7.50)

CT confirmed a right upper lobe lung tumour (Figure 1) with mediastinal nodes and liver metastases (T3, N2, M1b). During her admission serum calcium spontaneously dropped to 1.67mmol/l (Figure 2) and potassium levels to 2.0mmol/l.

Calcium and potassium levels were normalised with aggressive electrolyte replacement.

The association of a primary lung tumour, new-onset diabetes, hypertension and hypokalaemia suggested the possibility of ectopic ACTH.

A random cortisol was >4140nmol/l, and 1mg overnight dexamethasone test showed failure of cortisol suppression with cortisol >4140nmol/l & plasma ACTH 1197 (reference <47) ng/L.

Figure 1 - CT Chest

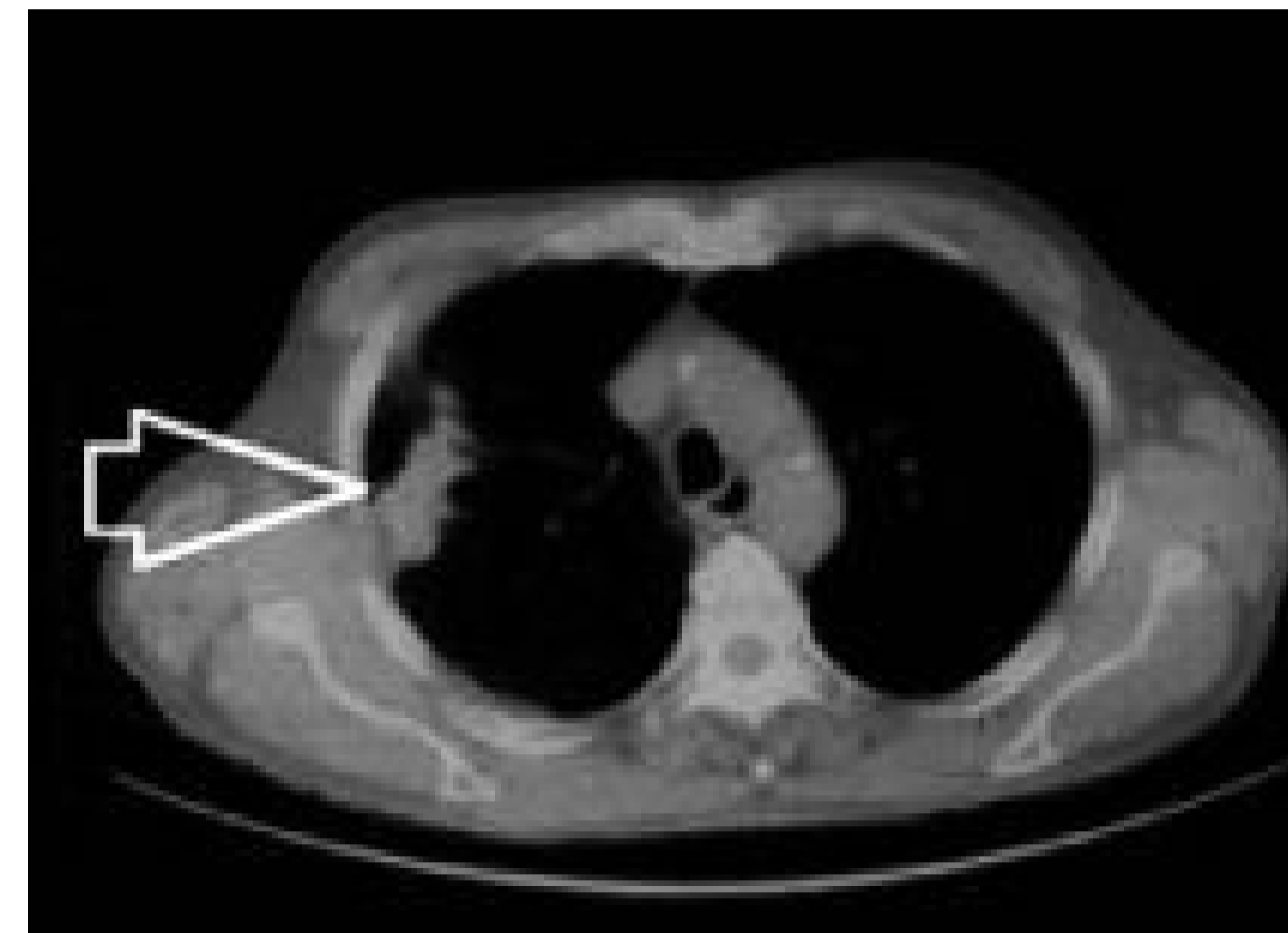
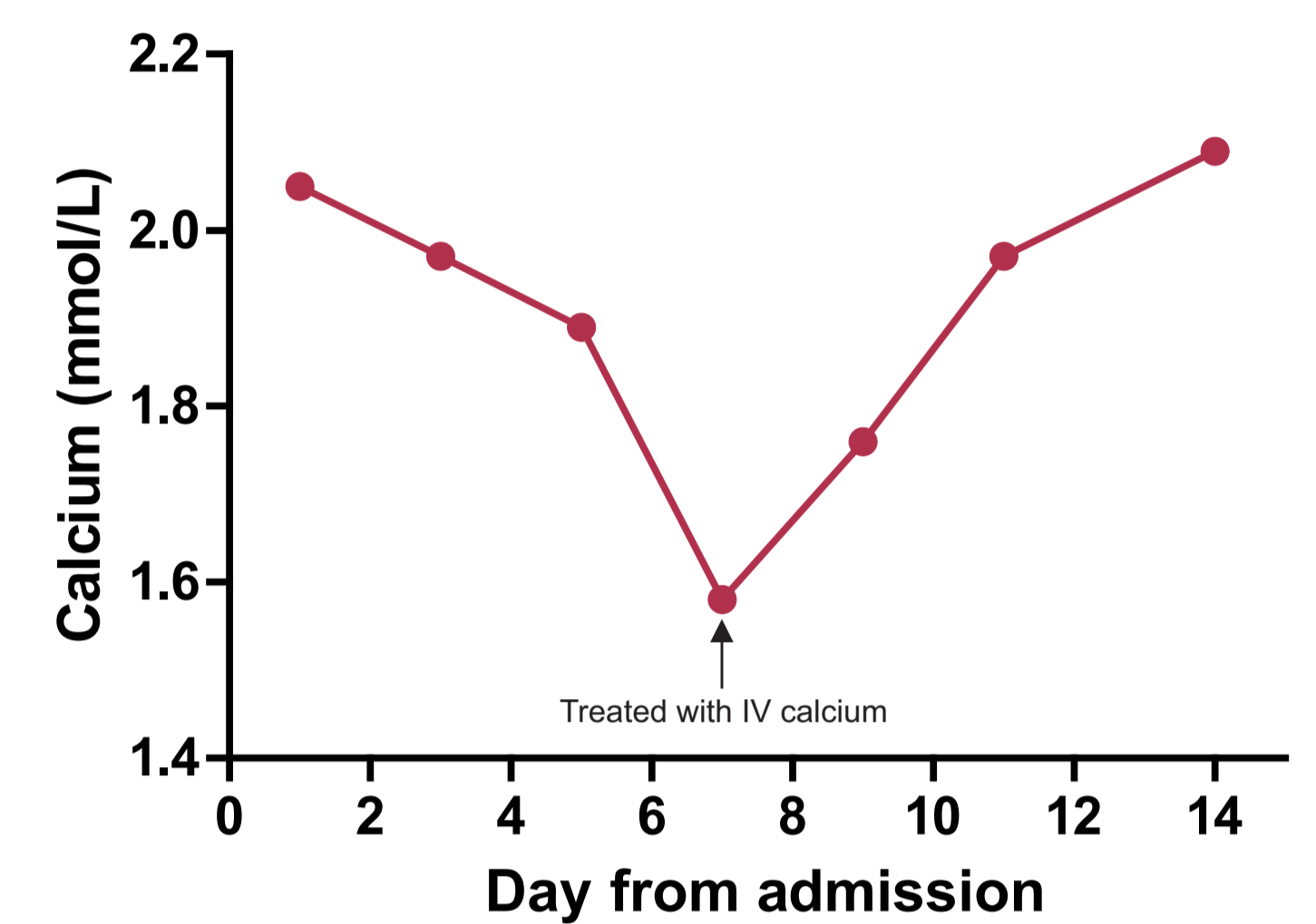


Figure 2 - Corrected Calcium



A diagnosis of Cushing's syndrome secondary to ectopic ACTH production was made.

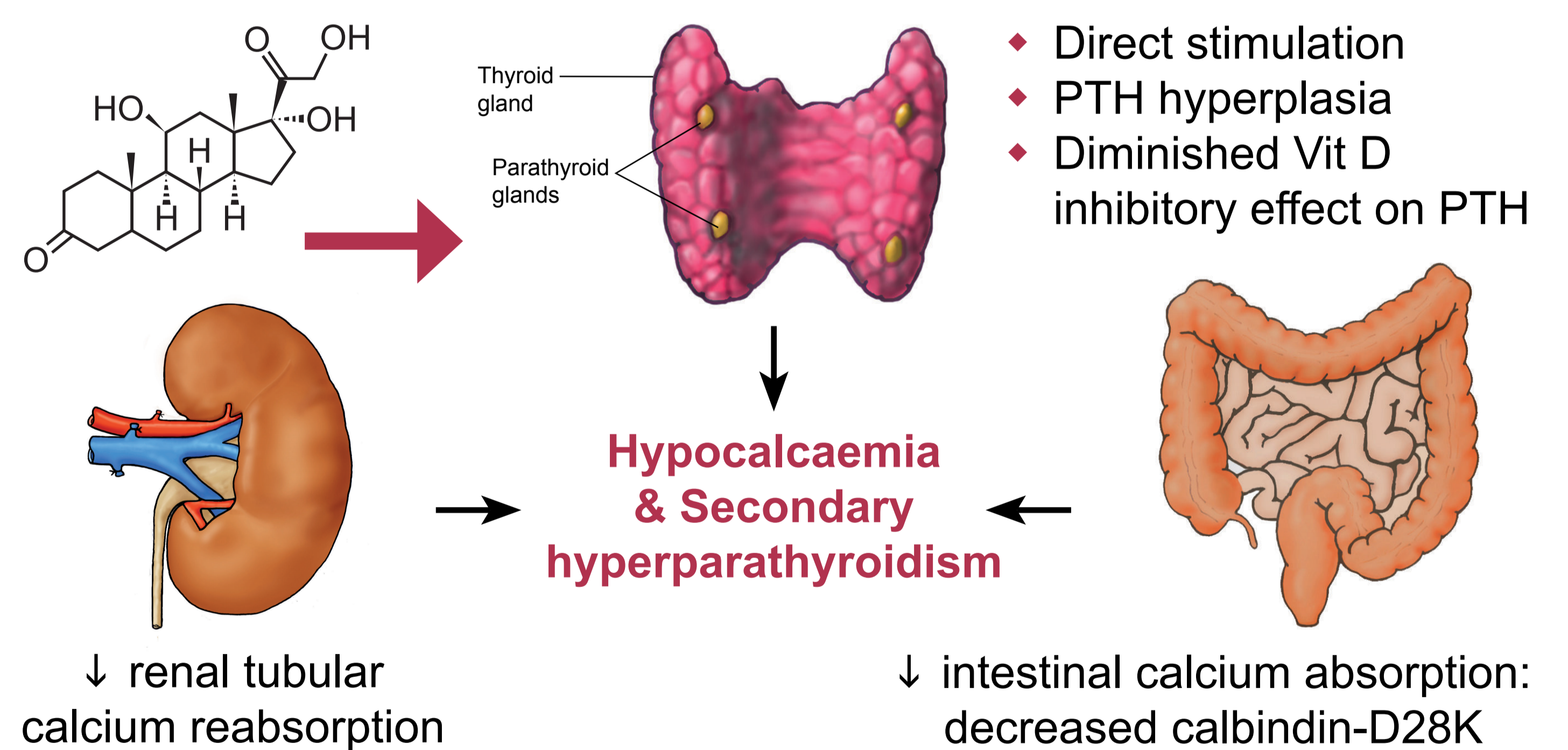
Liver biopsy established a diagnosis of metastatic poorly differentiated neuroendocrine carcinoma of small cell type from a lung primary.

Discussion

Hypercortisolism inhibits vit D action by the following mechanisms:

- ◆ Decreases number of Vit D receptors
- ◆ Increases Vit D degradation and associated with serum 25 (OH) D deficiency
- ◆ Reduces 1 - alpha hydroxylation Vit D

Possible mechanisms of hypocalcaemia in hypercortisolism



Conclusion

This case highlights severe hypocalcaemia can occur in the presence of ectopic ACTH production.

References

- ◆ Gennari C, Avioli V (1984) et al , Journal of clinical investigations, 36: 245-252
- ◆ Chen TL, Morey-Holton E (1982) et al, Journal of Biological Chemistry, 285: 4350-4355
- ◆ C.M.M.Lanna ,et al Braz J Med Biol Res, Feb 2002, 35(2)229-236
- ◆ Skversky, et al (2011) JCEM 96(12) 1-8

