

SDHB mutation and a large asymptomatic paraganglioma in a young woman: the importance of taking a good family history

A patient case summary

S. Foster^[i], Dr. M. Levy^[ii], Mr. D. M. Lloyd^[iii], Dr. J. Barwell^[iv]

^[i] Stuart Foster, Final Year Medical Student at Leicester Medical School, ^[ii] Dr. Miles Levy, Consultant Physician and Endocrinologist at University Hospitals Leicester, ^[iii] Mr. David Lloyd, Consultant Hepatobiliary and Laparoscopic Surgeon and Honorary Senior Lecturer in Cancer Studies at University Hospitals Leicester, ^[iv] Dr. Julian Barwell, Senior Lecturer in Cancer Genetics and Honorary NHS Cancer Genetics Consultant at University Hospitals Leicester

Introduction

This case illustrates the importance of taking a good family history in the context of a familial gene mutation associated with tumour formation. This patient is of interest as she is young, asymptomatic and otherwise well. However, a screening CT scan due to her notable family history of renal cancer led her to undergo major surgery.

SDHB Mutations

- The succinate dehydrogenase complex subunit B (SDHB) gene encodes for one of the four subunits of succinate dehydrogenase.
- Mutations of this gene are a major cause of hereditary paraganglioma and pheochromocytoma.
- Such tumours have a high rate of malignancy, making prompt detection and treatment paramount.

Patient Presentation

- A 23-year old woman (III2 in Fig. 1) was referred to endocrine clinic following confirmation of an SDHB mutation (c.136C>T).
- Her family was screened when a relative underwent a medical and a significant family history of renal tumours was discovered (Fig. 1).

Investigations

- The patient had no symptoms of catecholamine excess, no back or abdominal pain and normal urinary catecholamines and metanephrines.
- CT scan of the chest and pelvis and MRI scan of the head and neck and skull base were normal.
- The CT scan of the abdomen (Fig. 2) revealed a large, heterogeneously enhancing mass in the right para-aortic region measuring 10cm X 6.3cm X 11.2cm, arising from the organ of Zuckerkandl.
- MIBG scan (Fig. 3) showed no uptake in the area of the tumour, indicating a non-functional paraganglioma.

Figure 1: Pedigree

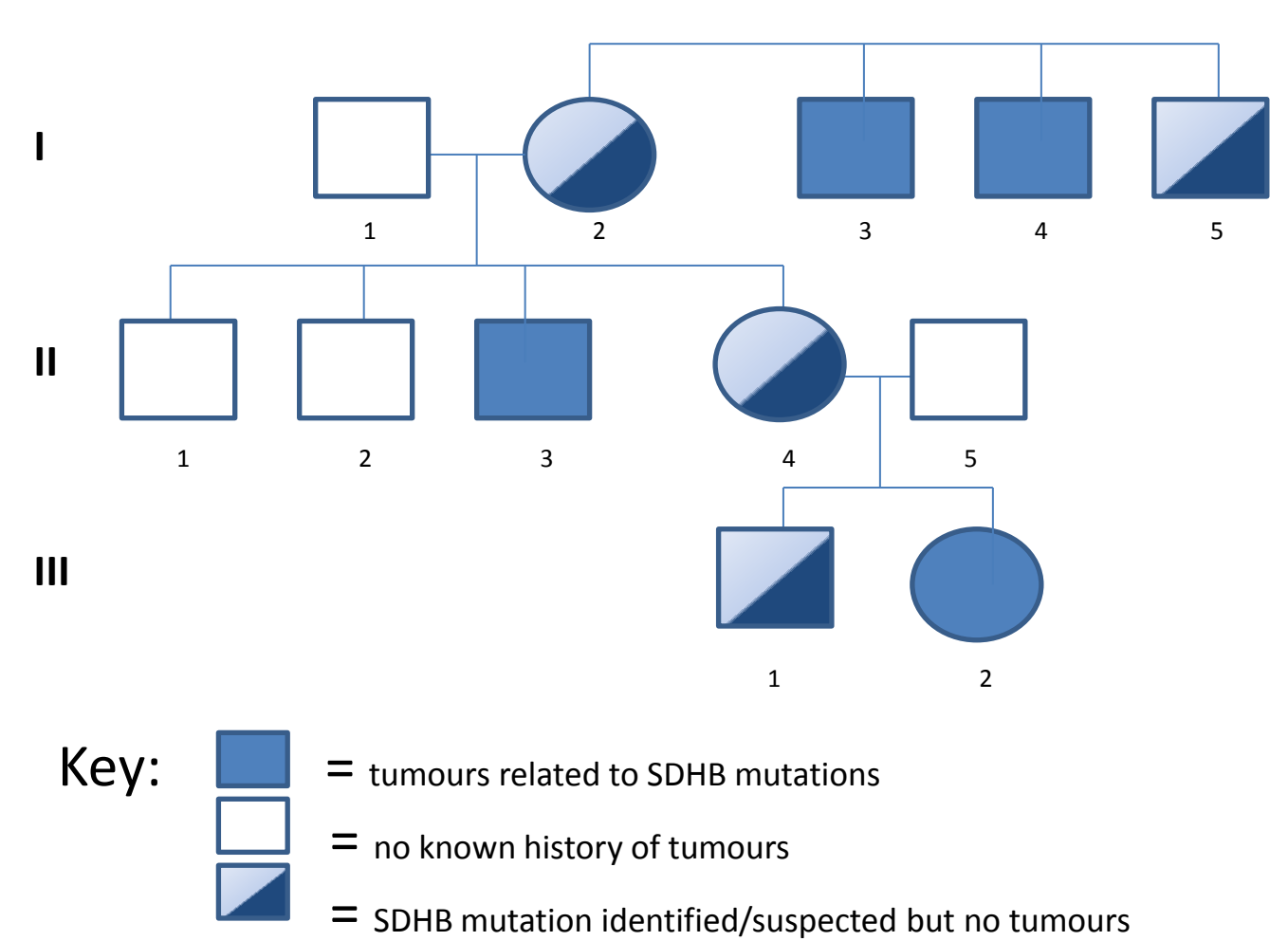


Figure 2: CT scan of abdomen

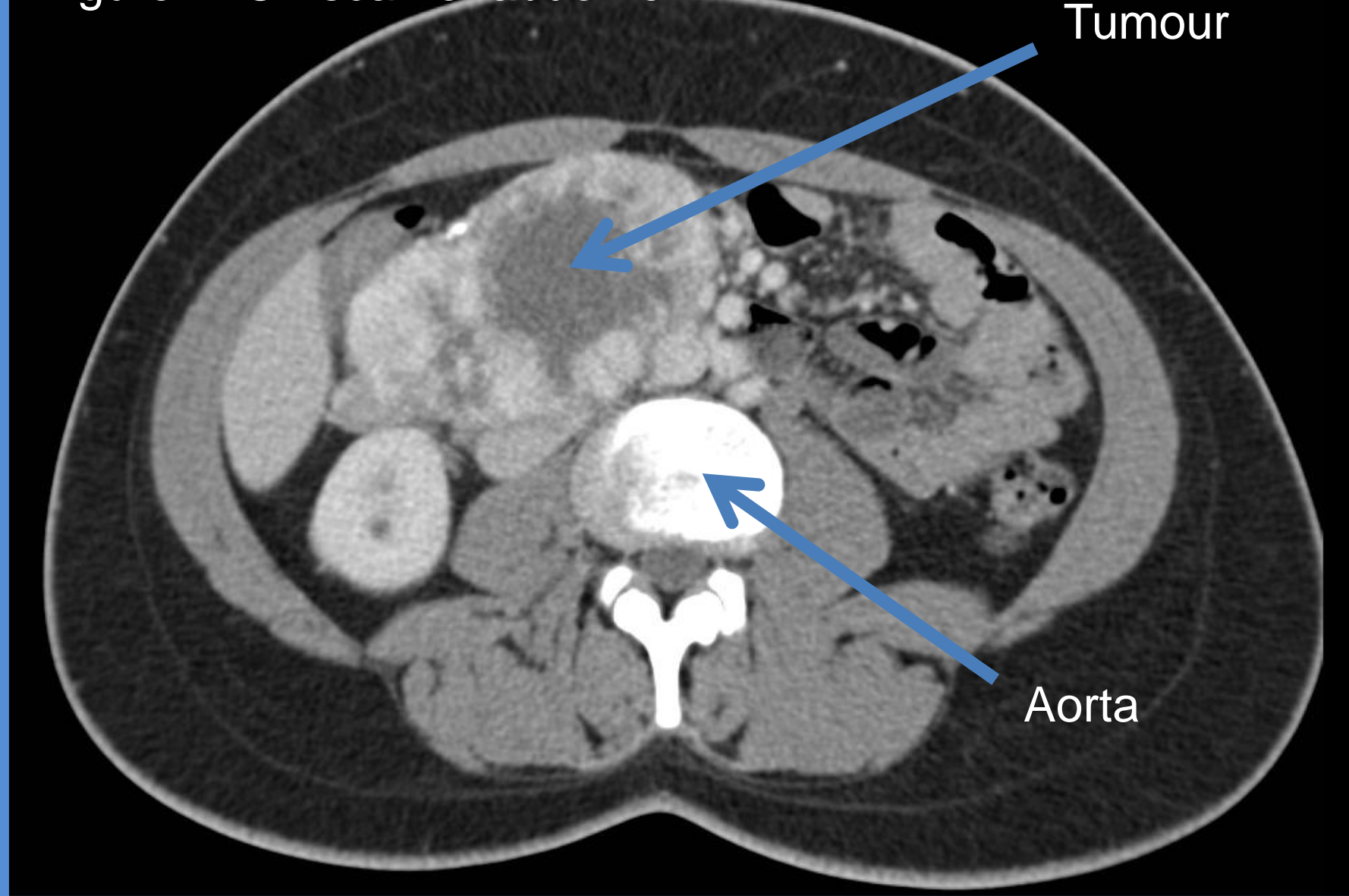
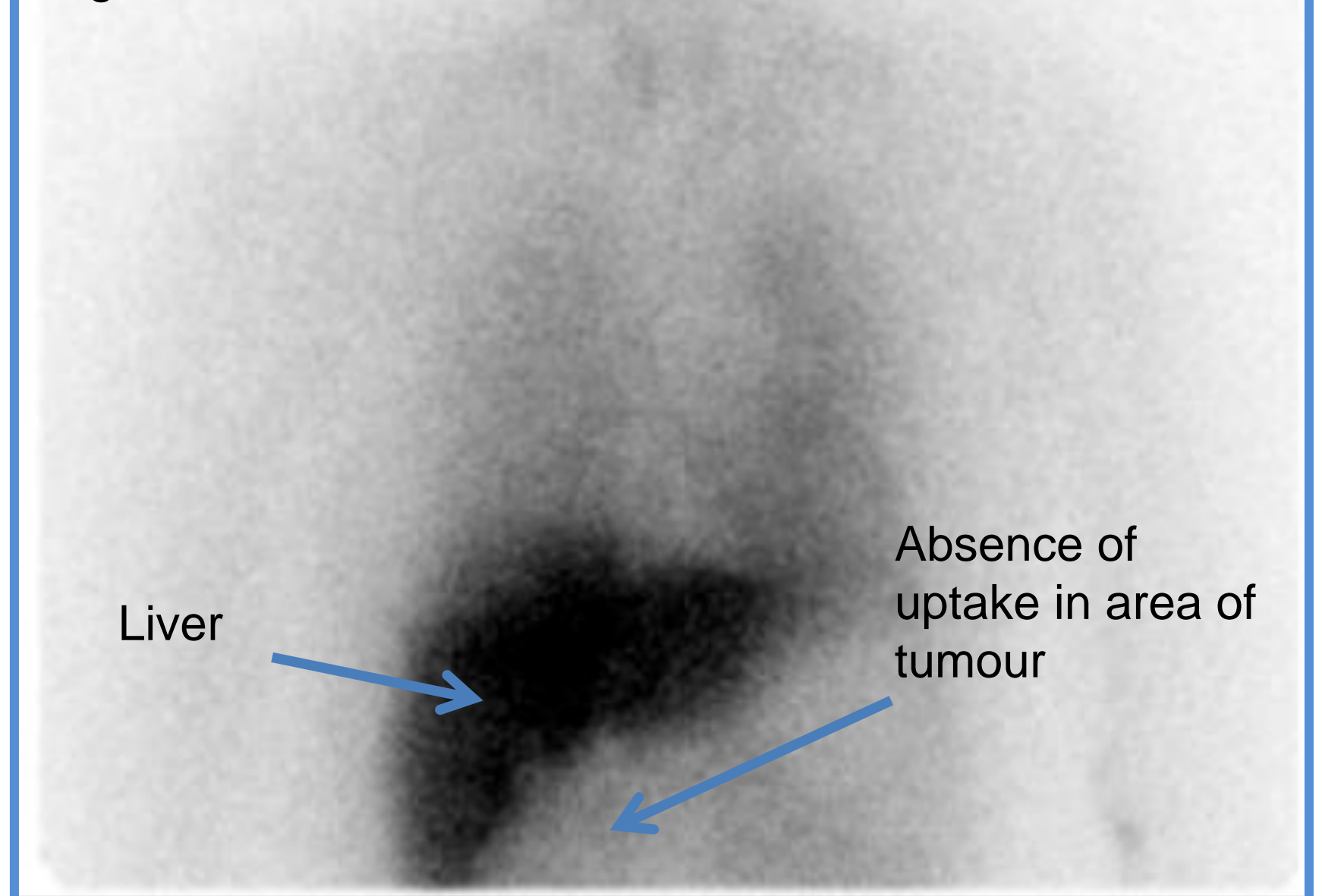


Figure 3: MIBG scan



Surgery

- Laparoscopic surgery was not possible due to the vascularity of the tumour and its close proximity to the aorta.
- Laparotomy with resection of the paraganglioma and removal of the inferior mesenteric artery was uneventful.
- Biopsy was taken and histology found there to be no adrenal gland tissue and the mass to be highly vascular. Immunohistochemistry revealed Zellballen nests with intervening vascularised stroma – typical features of paraganglioma (Fig. 4).

Conclusion

- This case demonstrates the importance of considering SDH mutations in patients with a strong family history of renal cancer.
- Due to non-penetrance, a three-generation family history is necessary as the relevant diseases may 'skip' a generation.
- This asymptomatic young woman had a very large tumour which would not have been diagnosed if the physician conducting the medical had missed the family history.
- The patient is currently well and has an annual urinary catecholamine test and imaging every two years.
- Her brother is under investigation.

Figure 4: H&E (Mag X 400)

